



Australasian  
Society of  
Cosmetic  
Dermatologists

IN THIS ISSUE

Classification and  
management of post  
acne scarring

Procedural options  
for acne scar  
rehabilitation

Acne scarring in  
skin of colour  
Tips and tricks

ACNE 2

OPINIONS AND PROGRESS IN  
**Cosmetic Dermatology**



VOLUME 02 / ISSUE 03 / DECEMBER 2022

Australasian Society of Cosmetic Dermatologists



GALDERMA

EST. 1981

# DON'T LET ACNE LEAVE ITS MARK<sup>\*1,2</sup>

\*Up to 95% of patients with acne are affected by post-acne scarring<sup>1,2</sup>

Acne can scar you physically and emotionally.<sup>1-5</sup> With its strong anti-inflammatory effect,<sup>6</sup> Epiduo<sup>®</sup> Forte (0.3% adapalene/ 2.5% benzoyl peroxide) is a once-daily topical gel with the power to clear up acne and reduce risk of scarring.<sup>6-8††</sup>



A CLEARER TOMORROW STARTS TODAY

†In a meta-analysis of pooled data from three multicenter, randomised, double-blind, vehicle-controlled, parallel-group studies in adult and teen-aged women, Epiduo<sup>®</sup> Forte met the co-primary endpoints of success rate (proportion of patients rated 'clear' IGA 0 or 'almost clear' IGA 1) and median percent change in acne lesion from baseline to Week 12.

††In a multicentre, randomised, investigator-blinded, vehicle-controlled, split-face study of 67 patients with moderate and severe inflammatory acne, Epiduo<sup>®</sup> Forte met the primary endpoint of atrophic acne scar count per half face at Week 24.

**PBS information:** This product is not listed on the PBS.

PLEASE REVIEW THE PRODUCT INFORMATION BEFORE PRESCRIBING,  
AVAILABLE VIA THE QR CODE ON THE RIGHT



**References:** 1. Layton AM, *et al. Clin Exp Dermatol* 1994;19(4):303–308. 2. Tan J, *et al. J Drugs Dermatol* 2017;16(2):97–102. 3. Chuah SY and Goh CL. *J Cutan Aesthet Surg* 2015;8(3):153–158. 4. Dunn LK, *et al. Dermatol Online J* 2011;17(1):1. 5. Hazarika N and Archana M. *Indian J Dermatol* 2016;61(5):515–520. 6. Epiduo<sup>®</sup> Forte Approved Product Information. 7. Stein Gold L, *et al. Am J Clin Dermatol* 2016;17(3):293–303. 8. Dreno B, *et al. Am J Clin Dermatol* 2018;19(2):275–286.

©Galderma Australia Pty Ltd, Suite 4, 13B Narabang Way, Belrose NSW 2085. From 2023: Level 18, 1 Denison Street, North Sydney, NSW 2060. ABN 12 003 976 930. Distributed in NZ by Healthcare Logistics, 58 Richard Pearse Drive, Airport Oaks, Mangere 2022, NZ. Phone: 1800 144 944 (AUS), 0800 174 104 (NZ). Fax: +61 (2) 9986 1699. AU-EFG-2200002. GAL0064. October 2022.



Australasian  
Society of  
Cosmetic  
Dermatologists

[www.ascd.org.au/  
medical\\_journal](http://www.ascd.org.au/medical_journal)

## Co-Editors-in-Chief

Clinical Prof Saxon D Smith  
Dr Adrian Lim

### Founding Editor

Prof Greg J Goodman

### Guest Editor

Dr Nina Wines  
Dr Shobhan Manoharan

### Publishing Coordinator

Geoff Brown  
— Research Review Australia Pty Ltd

### Publication Reviser

Carmen Innes BSc

### Publication Design

Kim Jackson BCGD(Hons)

All literary matter in the OPCD is covered by copyright, and must not be reproduced, stored in a retrieval system, or transmitted in any form by electronic or mechanical means, photocopying, or recording, without written permission.



Follow us on Twitter:  
[@theASCD](https://twitter.com/theASCD)



and like us on Facebook:  
[https://www.facebook.com/  
ASCDorgau/](https://www.facebook.com/ASCDorgau/)

OPINIONS AND PROGRESS IN

# Cosmetic Dermatology

VOLUME 02 / ISSUE 03 / DECEMBER 2022

ACNE 2

## Editorial Committee

For full details of Editorial Advisory Group members, please go to  
<https://www.ascd.org.au/journal>

Dr Katherine Armour  
Assoc Prof Philip Bekhor  
Dr Anina Fitzgibbon  
Assoc Prof Michael Freeman  
Prof Greg J Goodman (Founding editor)  
Dr Adrian Lim (Co-editor-in-chief)  
Dr Davin Lim (Industry editor)  
Dr Shobhan Manoharan  
Dr Cara McDonald  
Dr Michael Rich  
Dr Alice Rudd  
Clinical Prof Saxon D Smith (Co-editor-in-chief)  
Dr Belinda Welsh  
Dr Nina Wines  
Dr Lee-Mei Yap

The ASCD follows guidelines on ethical publishing, including editorial independence, produced by the International Committee of Medical Journal Editors (<http://www.icmje.org/recommendations/>), the World Association of Medical Editors (<http://www.wame.org/about/policy-statements>) and the Committee on Publication Ethics (<http://publicationethics.org/resources>).

## Advertising

### Contact the ASCD

E: [ascd@ascd.com.au](mailto:ascd@ascd.com.au)

### Subscriptions

Free open access journal

E: [subscriptions@ascd.org.au](mailto:subscriptions@ascd.org.au)

### Instructions to authors

<https://ascd.org.au/ascd-journal/>

### Sales Manager

Gina Samuels

The Production House Group

Email: [gina@tphe.com.au](mailto:gina@tphe.com.au)

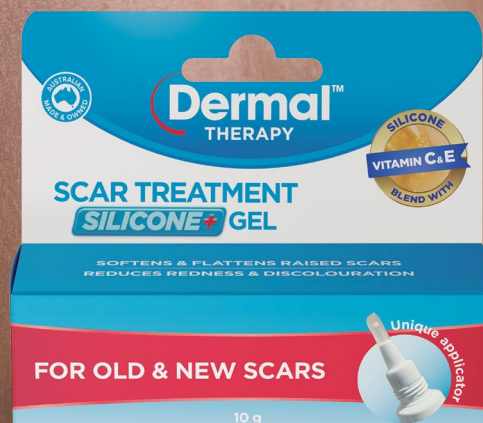Tel: 03 9020 7056

The Australasian Society of Cosmetic Dermatologists Medical Journal, Opinions and Progress in Cosmetic Dermatology (ASCD-MJ, OPCD) is published quarterly by the Australasian Medical Publishing Company Proprietary Limited (AMPCo), a wholly owned subsidiary of the Australian Medical Association (AMA). The statements or opinions that are expressed in the ASCD reflect the views of the authors and do not represent the opinions or policies of the ASCD or the AMA unless so stated. None of AMPCo, the AMA or any of its servants and agents will have any liability in any way arising from information or advice that is contained in the ASCD. Although all accepted advertising material is expected to conform to ethical and legal standards, such acceptance does not imply endorsement by the ASCD. The ASCD is intended for medical professionals and is provided without warranty, express or implied.



**Dermal™**  
THERAPY

The latest  
innovation in  
**OTC scar**  
treatment  
is here.



- ☒ Visibly fades new and old scars
- ☒ Softens & flattens scars
- ☒ Reduces redness & discolouration
- ☒ Powered by Silicone+ technology, enriched with Vitamin C & E
- ☒ Unique precision soft rubber applicator tip



[dermaltherapy.com.au](http://dermaltherapy.com.au)





## Welcome to the Acne Scarring issue – the second instalment of the two-part series on Acne.

We are excited to have Drs Nina Wines and Shobhan Manoharan as guest editors for this issue. They are prominent cosmetic dermatologists in Sydney and Brisbane respectively, and have produced a remarkable edition focusing on the intricacies of acne scar repair.

Acne scarring is a topic close to the heart of Professor Greg Goodman, founding editor of the journal, whose significant contribution on the subject is well reflected by the number of references to the Baron-Goodman Scar Scale throughout this issue.

This edition brings back the popular “How I Do It” procedural clips on various aspects of acne scar repair, which will greatly add to the educational experience for our subscribers.

The journal is now open to article submissions on all aspect of cosmetic dermatology including therapeutics, physical procedures, and skin care. We welcome case studies, case series, original studies, review articles and procedural tips and tricks, opinion pieces and correspondence letters.

As always, we appreciate any feedback to help us improve on future editions and meet your education needs.

### Co-Editors in Chief

Dr Adrian Lim

Clinical Professor Saxon D Smith

## Contents

### PAGE

- 1 / **Acne 2 – Guest editorial** (part 1)  
Nina Wines
- 2 / **Acne 2 – Guest editorial** (part 2)  
Shobhan Manoharan
- 4 / **Classification and management of less severe surface predominant post acne scarring**  
Greg Goodman
- 17 / **Classification and management of severe atrophic post acne scarring**  
Greg Goodman
- 32 / **Acne and acne scarring in skin of colour**  
Shi Yu Derek Lim, Hazel H Oon, Chee Leok Goh
- 41 / **Procedural options for acne scar rehabilitation**  
Nina Wines, Jill Waibel, David J. Goldberg, Rebecca Quiñonez, Shreya Andric, Elizabeth Dawes-Higgs, Andrea Tomizawa, Ishana Dixit
- 53 / **Single session customised multimodal acne scar rehabilitation: An overview and guide to treatment planning**  
Nina Wines, Jill Waibel, Rebecca Quiñonez, Shreya Andric, Elizabeth Dawes-Higgs, Andrea Tomizawa, Ishana Dixit
- 66 / **Energy-based devices for the treatment of acne scarring**  
Shobhan Manoharan
- 72 / **Are we too reliant on energy-based devices for the treatment of acne scarring?**  
Davin Lim
- 75 / **Management of elevated acne scars**  
Xin Lin Wong, Stephen Shumack
- 83 / **Tips and tricks for revising acne scars – what I have learned over 15 years**  
Davin Lim

- 87 / **Videos – How I do it**



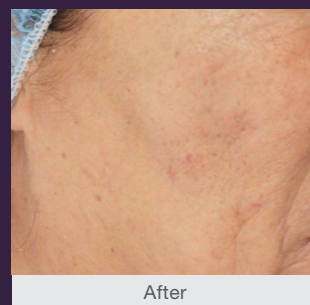
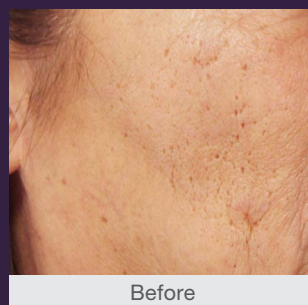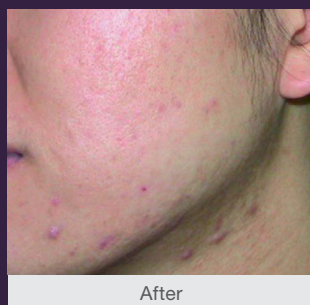
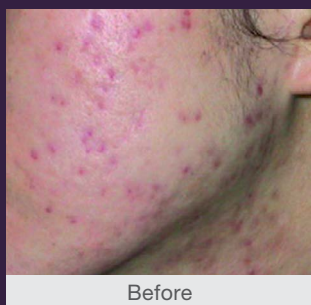
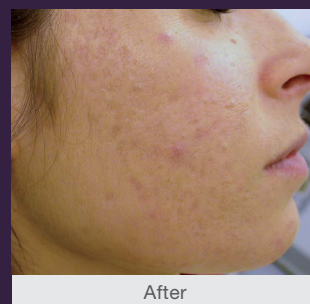
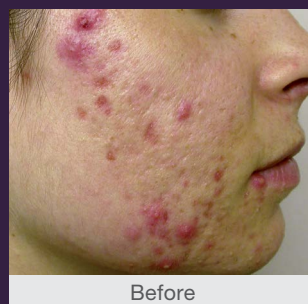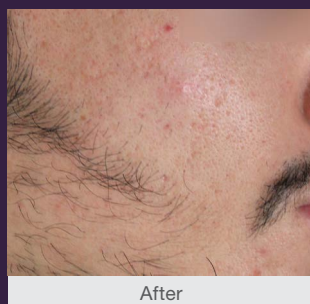
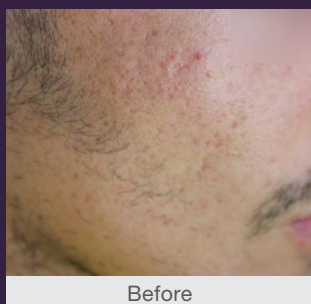


# Treat acne scarring with Nordlys™



The Nordlys system's Selective Waveband Technology (SWT®) delivers precision narrowband IPL<sup>1,2</sup> for improved comfort and low downtime, enabling the use of multiple technologies in a single session – all without compromising results.<sup>1,2,3,4</sup>

- Ellipse IPL™ technology improves the appearance of acne vulgaris and red macules<sup>5</sup>
- The combined nonablative Frax 1550 nm and 1940 nm wavelengths provide deep and shallow resurfacing for smooth, brilliant skin.



Images supplied by Nordlys users. All photos are unretouched.

Call **1300 CANDELA (226 335)** or visit **candelamedical.com**

1. Nordlys User Manual, 2021. 2. Candela, data on file, 2022. 3. Bjerring P, et al. *Lasers Surg Med.* 2004;34(2):120-126. 4. Schallen KP, Murphy M. Treatment of photodamaged skin with a combined dual-filter intense pulsed light and fractional 1550-nm laser system. *Lasers Surg Med Suppl.* 2020;52(S32). 5. Chang SE, Ahn SJ, Rhee DY, Choi JH, et al. Treatment of facial acne papules and pustules in Korean patients using an intense pulsed light device equipped with a 530- to 750-nm filter. *Dermatol Surg.* 2007;33(6):676-679. 6. Ellipse Nordlys CE Mark, January 2020.





# Acne 2 – Guest editorial (part 1)

**Guest Editor:** Nina Wines

Correspondence: Dr Nina Wines [info@drninawines.com](mailto:info@drninawines.com)



CLICK IMAGE TO LINK TO VIDEO

DURATION\_01:42

Wines N. Acne 2 – Guest editorial (part 1). *Opin Prog Cosmet Dermatol* 2022;2(3):1.

I am delighted to be guest editor for this issue devoted to acne scarring as a follow-on companion to the most recent edition on acne. Acne scars remain one of the most detrimental and long-term consequences of patients dealing with acne vulgaris. Advent of technology has enabled this revolutionary era in acne scar management resulting in an offering of a range of effective modalities to practitioners. This edition focuses on demystifying acne scar management so as to provide a gateway to fully understanding the armamentarium of options for treatment that can be individualised to scar severity, skin type and patient needs.

Within we present the opinions of local and international leading experts in the field of managing acne scarring. Prof Greg Goodman is our own well published local expert who has been instrumental in determining how we classify and grade acne scarring for decades. This has shaped acne scar research internationally. Very seldom do you read a paper relating to this topic without there being a mention of the “Goodman and Baron” acne scar classification. Greg begins by exploring management options segregated in two parts: less severe surface predominant post acne scarring versus severe atrophic post acne scarring.

Prior to managing acne scarring physicians require a full understanding of the array of procedural options that are available for acne scar rehabilitation. Within this edition an overview of various modalities is presented outlining their pros and cons. As it can be confusing to determine which treatment to choose, international expert Dr Firas Al-Niaimi provides his pearls based on decades of experience.

Energy-based devices have shaped the management of acne scarring. Practitioners need to be knowledgeable and at times nimble in device selection. Dr Shobhan Manoharan presents an excellent article reviewing energy-based devices that are currently used for acne scarring. Laser-assisted drug delivery is an expanding field in dermatology. Dr John Sullivan explores the evolving use of this technique for acne scarring.

Excellent results can also be achieved with non-energy-based solutions such as injectables, physical therapies and surgical techniques. Procedural practical tips and tricks are always helpful. An interesting comparison of three expert approaches to fillers for acne scarring is presented. Greg Goodman also outlines his bilevel approach to subcision. Dr Davin Lim details valuable practical tips and tricks for his approach to acne scarring.

Treatment burden is a concern for our patients. Maximising treatment efficacy and efficiency by combining multiple procedures in a single session is becoming increasingly important. It was wonderful to collaborate with Dr Jill Waibel, and Dr David Goldberg et al. to detail the procedural options available for acne scar management and how to cognitively put all of these together to plan effective single-session multimodal acne scar rehabilitation so as to optimise outcomes for patients.

Practitioners well versed in managing skin of colour appreciate some of the adaptations that can be made to improve outcomes. We thank Shi Yu Derek Lim, Hazel Oon and Chee Leok Goh for their pearls of wisdom and experience.

Ultimately, I hope this edition provides effective take-home tools for your everyday clinical care.

Please enjoy.  
**Dr Nina Wines**



---

# Acne 2 – Guest editorial (part 2)

**Guest Editor:** Shobhan Manoharan

Correspondence: Dr Shobhan Manoharan ✉ [shobhan@manoharangroup.com.au](mailto:shobhan@manoharangroup.com.au)

Manoharan S. Acne 2 – Guest editorial (part 2). *Opin Prog Cosmet Dermatol* 2022;2(3):2.

---

**I**t has been an honour and a pleasure to guest edit this issue with Nina, on a topic that both of us are so passionate about.

Acne scarring results in a significant burden of emotional and psychological distress for many young and older individuals. It is often inadequately addressed in medical practice, and its impact is often underestimated by physicians and the general community.

All of us who have treated individuals with scars understand how this can be enormously transformative to a patient's self-esteem, confidence, social and professional standing.

The treatment of acne scarring has progressed significantly over the last two decades, and the evolution of surgical techniques, energy-based devices, injectables, novel combination treatment modalities, and the ability to combine acne scar treatments while patients are under active medical management for acne, have all led to earlier intervention, better overall outcomes, and reduced complications.

We live in an era where most acne scarring can be improved, and it is a delight to be able to be involved in highlighting treatment options, and to harness the experience and opinions of local and international scar experts, to put together this issue for you.

In this issue, we have combined reviews with video clips which we hope will help vividly illustrate the options and techniques of acne scar treatments.

Please enjoy, and we hope that you too will come onboard the journey of treating scars and changing lives with us.

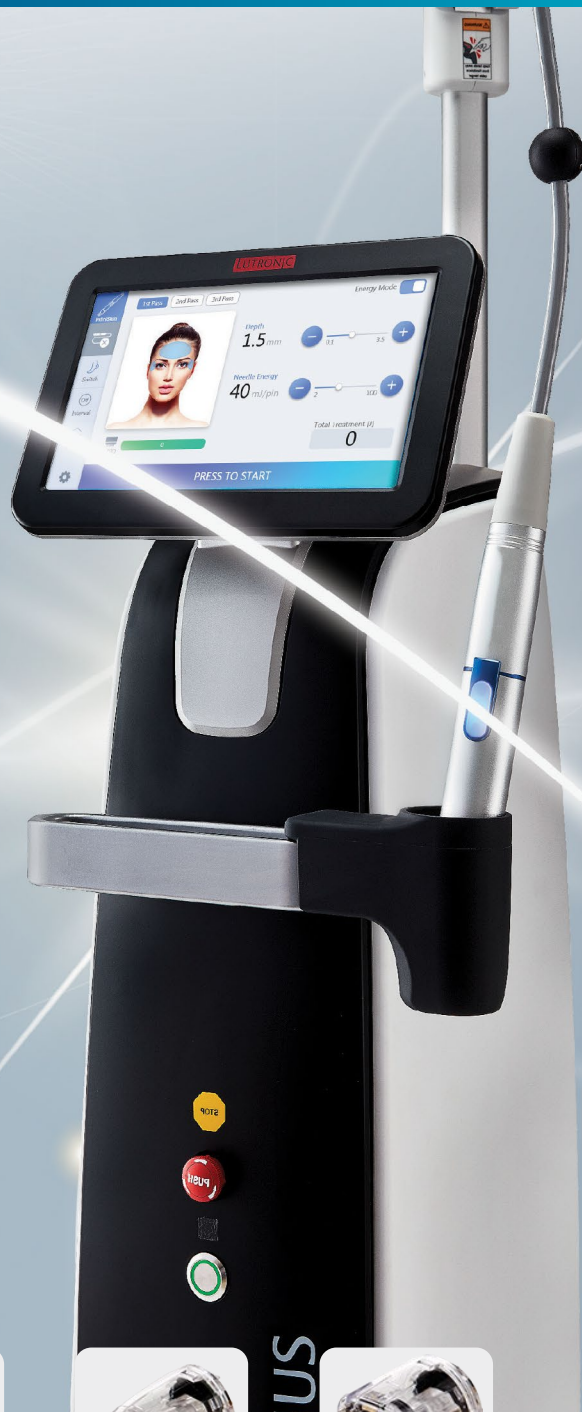Best regards  
**Dr Shobhan Manoharan**



# GENIUS™

INTELLIGENT MICRONEEDLING  
AND RF IN ONE PLATFORM

- Treat acne and surgical scars with the state-of-the-art Genius™. Combining the power of two technologies in one platform.



#### Genius

Standard tip for face & body:  
G49D (7 x 7 Pins,  
10 X 10mm)



#### GeniEye

Eye area/  
Wrinkles: P14D  
(2 x 7 Pins)



#### GeniScar

Isolated scars/  
Small areas:  
P16D (4 x 4 Pins)



#### GeniBody

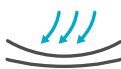Body area:  
M49D (7 x 7 Pin,  
20 x 20mm)  
4X larger



Neck lifting



Wrinkles



Sagging skin



Stretch marks



Melasma



Scars



# Classification and management of less severe surface predominant post acne scarring


Greg Goodman<sup>1,2</sup>

1. Monash University, Clayton, VIC, Australia

2. University College of London, London, UK

Correspondence: Professor Greg Goodman [ggg@div.net.au](mailto:ggg@div.net.au)

Disclosures: *none*



[CLICK IMAGE TO LINK TO VIDEO](#)

DURATION\_02:49

**OUTLINE:** This review covers the assessment and management of milder forms of post acne scarring (Goodman Baron scale: grades 1–2). Less severe acne scarring consists of surface predominant changes such as erythematous, hypopigmented and hyperpigmented marks, as well as mildly atrophic or hypertrophic scarring. Although objectively less severe, these scars may still be distressing for patients. Suggested treatment options are matched to the various scar types, along with efficacy grading. Procedural options include vascular lasers, intense pulsed light (IPL), pico lasers, chemical peels, microdermabrasion, fillers, skin needling, fractionated energy devices, and pigment transfer procedures for hypopigmented scars.

**KEYWORDS:** acne scarring, hypopigmented scars, hyperpigmented scars, erythematous scars, atrophic scars

Goodman G. Classification and management of less severe surface predominant post acne scarring. *Opin Prog Cosmet Dermatol* 2022;2(3):4-15.

## Introduction

Post acne scarring may be thought of in terms of what type of scar we are viewing as well as what it means for the patient, that is subjectively as well as objectively.

Usually, a patient will have a burden of disease related to the severity of the scarring that one sees objectively. However, this is not always the case with some patients coping well with severe scarring, whilst others battle with what objectively looks like a much lesser level of scarring.

The milder forms of scarring from an objective point of view, mainly affect the surface of the skin and the superficial dermal structures. Using a section of a previously described acne scarring categorisation<sup>1</sup> (Table 1), an attempt is made to address the management of surface predominant acne scarring. More severe examples of post acne scarring will be addressed in a further article in this journal.

Surface predominant acne scarring really comprises colour and surface texture. Although this surface texture may be mildly atrophic or hyperplastic, attention is limited here to atrophy.

Colour is highly important to patients, as we tend to judge the health and age of an individual based partly on the evenness of colour of their skin. Several studies have indicated that health perception of an individual is more centred on evenness of colour than aspects such as wrinkles or topography<sup>2</sup> and that apparent attractiveness is also influenced by alterations in the evenness of skin colour.<sup>3,4</sup> Colour change appears synergistic with wrinkles in apparent age perception.<sup>2</sup> This type of scarring, although flat, is distressing to patients as it is obvious at a distance without makeup. Many female patients will apply concealers and makeup thickly to camouflage affected marks and render themselves liable to secondary comedonal changes of acne cosmetica. Many men will attempt beard growth or stubble to camouflage these areas where possible.

A full outline of the grading scale used in these articles is seen in Table 1.



Table 1. Grading scars according to burden of disease

Grade	Level of disease	Characteristics	Examples of scars
1	Macular disease	Red, brown, or white flat marks visible to patient or observer, irrespective of distance	Red, brown, or white flat marks
2	Mild disease	Mild atrophy that may not be obvious at social distances of ≥50 cm and may be covered adequately by makeup or the normal shadow of shaved beard hair in males or normal body hair if extrafacial	Mild rolling scars either in isolation or in hills and valleys
3	Moderate disease	Moderate atrophic scarring that is obvious at social distances of ≥50 cm and is not covered easily by makeup or the normal shadow of shaved beard hair in males or body hair if extrafacial, but is still able to be flattened by manual stretching of the skin	More significant rolling, shallow to deeper boxcar type scars
4	Severe disease	Severe atrophic scarring that is obvious at social distances of ≥50 cm and is not covered easily by makeup or the normal shadow of shaved beard hair in males or body hair (if extrafacial), and is not able to be flattened by manual stretching of the skin	Punched out atrophic (deep boxcar), ice pick, bridges and tunnels, gross atrophy, dystrophic scars

Grade 1 scarring

This describes abnormally coloured, macular disease, and includes red, brown, or white flat marks or scars visible to a patient or observer at any distance.

Red (erythematous) scars

This form of scarring is often no more than a phase in wound healing<sup>5</sup> and is likely to resolve or improve if inflammation is removed and the mark allowed to heal.

However, intervention may assist these scars or marks to heal faster and with superior outcomes.

These red scars or marks may occur anywhere where recent activity has occurred (Figure 1). In this case a variation of light emitting diode (LED) therapy and superficial peels was used to resolve active acne but leaving behind erythematous marks that would be expected to resolve with time or further intervention.

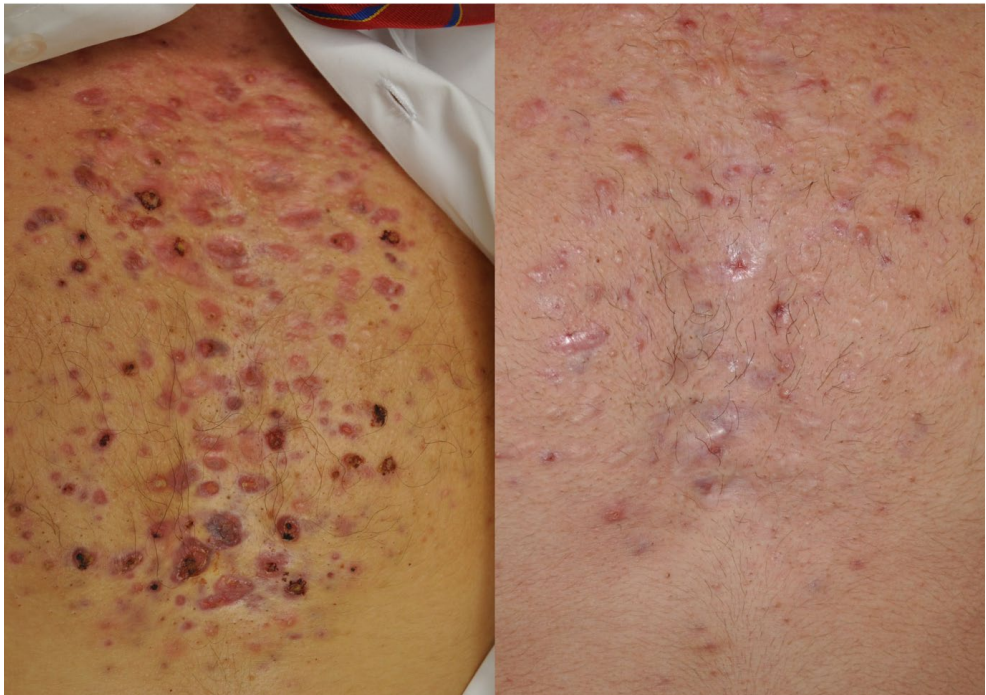

Figure 1: Erythematous and persistent textural scars before and after resolution of active acne with light emitting diode (LED) treatment and peels.

Grade 1 scars will tend to last longer on the body than the face as healing is slower on the body generally. Intervention is required if this process is not occurring in a timely fashion or where the patient is impatient for recovery. These marks are particularly seen during isotretinoin therapy. It was suggested that therapy should be delayed whilst the patient is on isotretinoin, because of the risk of scarring further with therapy. However, consensus papers have changed the way we approach treatment during isotretinoin therapy.<sup>6-8</sup> It may be that we have been providing a disservice to our patients by not treating these red scars and marks during their isotretinoin journey.

Resolving hypertrophic scars exhibit more prolonged erythema. This is most often seen in younger patients and may occur in facial or off face scarring. More than one treatment is required in most cases of erythematous acne scars.

## Energy-based devices

One of the more utilised therapies for red macular scars or marks is via energy-based devices. Vascular specific lasers and light sources are often utilised with varying levels of evidence. In 1995, pulsed dye laser (PDL) was reported in the treatment of keloid sternotomy scars, with improvement in scar height, skin texture, erythema, and pruritus<sup>9</sup> with further confirmation forthcoming in other studies.<sup>10</sup> The flash-lamp PDL was then used for treatment of erythematous scars.<sup>11</sup> In other studies, several treatments at monthly intervals were utilised with relatively short pulse duration millisecond treatment either with intense pulsed light (IPL) or PDL<sup>12</sup> or with low fluence Q-switched lasers.<sup>13</sup>

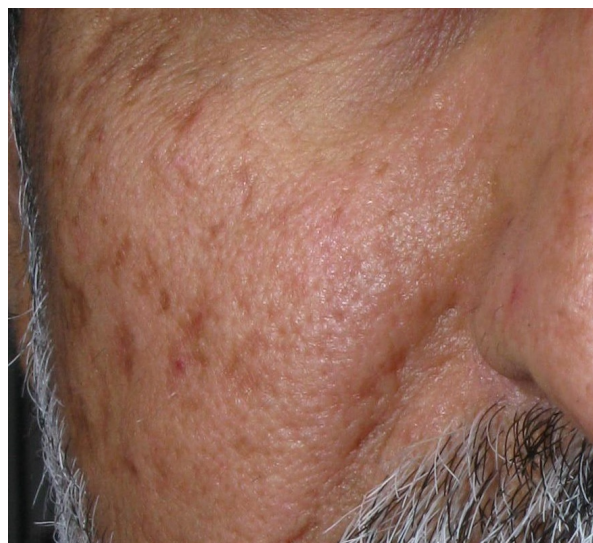Other scar types, assessed according to the ECCA (échelle d'évaluation clinique des cicatrices d'acné) scar classification system<sup>14</sup> utilising vascular specific treatments,<sup>15</sup> appear to have limited scar improvement scores. It is probably optimal to use vascular lasers in patients in whom the dominant scar type is erythematous, although it is worthwhile keeping in mind that it may have a positive effect on other atrophic and hypertrophic scar types if they are also present.<sup>16</sup>

### Key points

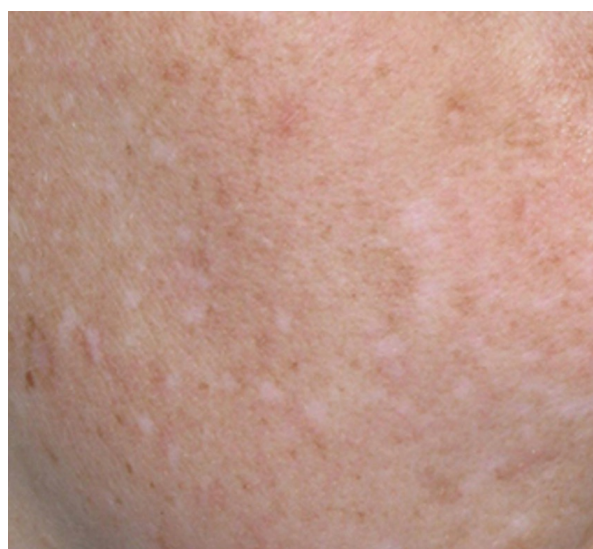1. Vascular lasers appear useful for erythematous scars, but multiple treatments may be necessary.
2. This may be true for macular or slightly elevated or depressed scars.
3. Vascular lasers may be useful in other non-coloured scar types.

## Pigmentation changes in scars and marks

Pigmented marks and scars may be a temporary or a long-term issue (Figure 2). Hypopigmented macules may be obvious or not and dependent on Fitzpatrick skin type and the presence or absence of any background hyperpigmentation (Figure 3). This induces a contrast that highlights the hypopigmented marks which do not tan with the skin or participate in any background increases in pigmentation such as melasma or poikiloderma (Figure 3).

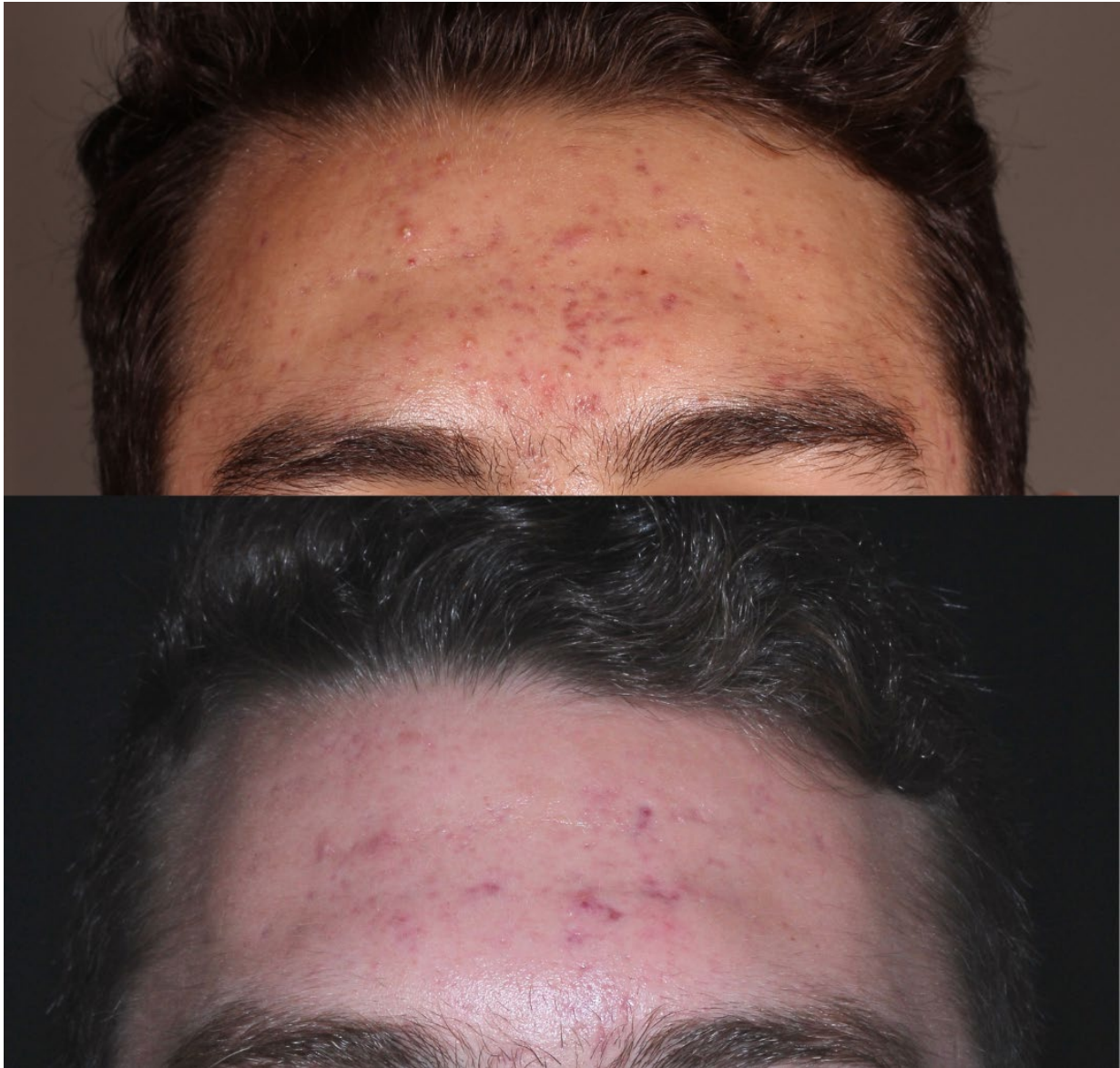

**Figure 2.** Post inflammatory hyperpigmented macules



**Figure 3.** Hypopigmented scars amongst a background of facial hyperpigmentation





**Figure 4.** Before and after LED and light chemical peel treatment of acne with mild post-inflammatory erythema and pigmentation

Hyperpigmented marks are often representative of active acne and post inflammatory hyperpigmentation and respond to time and bleaching preparations. Occasionally peeling and variations of LED may be useful in treatment (Figure 4).

### Fractionated lasers and devices, pigment lasers and intense pulsed light (IPL)

Fractionated lasers may sometimes be used for hypopigmented marks and scars on or off the face with significant improvement. In a pilot study, 51% to 75% reduction in hypopigmentation in six of seven patients was attained.<sup>17</sup> Thulium (1,927 nm) and fractionated pico lasers have been utilised in the treatment of hyperpigmentation and other aspects of acne scarring.<sup>18,19</sup>

Thulium may also be used to treat a hyperpigmented background, decreasing the contrast between these areas and any hypopigmented scars.

IPL has been used for treatment of atrophic and hypertrophic disease alone<sup>20</sup> or in combination with other therapies;<sup>21</sup> however, conclusive evidence for its efficacy with these scar types is insufficient.<sup>22</sup>

#### Key points

1. Fractionated lasers (especially 1550 nm) are useful for hypopigmented scars.
2. Fractionated thulium and pico lasers may be useful for hyperpigmented scars.
3. IPL may be useful in several scar types.

## Repigmentation procedural techniques

Hypopigmented scars may be additionally helped by more directed repigmentation procedures.<sup>23</sup> Agents such as topical latanoprost or bimatoprost may be added to resurfacing procedures to regain pigment.<sup>24,25</sup>

There have been scattered reports of repigmentation after manual dermabrasion<sup>26</sup> and microneedling.<sup>27</sup> Transfer of cultured and immediate non-cultured epidermal suspensions may also be somewhat useful in leucoderma<sup>28</sup> and an automated commercial kit

for trypsin dermal-epidermal separation allowing immediate autologous non-cultured epidermal suspension may be useful.<sup>29,30</sup>

### Key points

1. Bimatoprost and latanoprost alongside resurfacing techniques may be useful for hypopigmented scars.
2. Pigment transfer procedures such as automated trypsin digested epidermal cells may be useful adjuncts to the treatment of hypopigmented scarring.

**Table 2.** Treatment options according to scar type for grade 1 scars

Examples of scars	Treatment options
Erythematous flat marks	<b>Surface</b>
	Time*****
	Vascular lasers****
	IPL***
	Fractionated radiofrequency*** Fractionated non ablative lasers**
Hyperpigmented flat marks (post inflammatory marks)	<b>Volume, movement, surgery</b>
	No treatment options required
	<b>Surface</b>
	Optimised home skin care (bleaching agents, sun protection)***** Light strength peels +/- microdermabrasion*** Pico lasers (full field or fractionated)*** Fractionated lasers and other fractionated devices with assisted drug delivery** Other pigment lesion lasers or IPL*
	<b>Volume, movement surgery</b>
Hypopigmented macular scars	No treatment options required
	<b>Surface</b>
	Sunscreens and occasionally bleaching preparations to limit contrast** Skin care** Fractionated non ablative resurfacing** Pigment transfer procedures (blister grafting, autologous cell transfer)**
	<b>Volume, movement surgery</b>
	No treatment options required

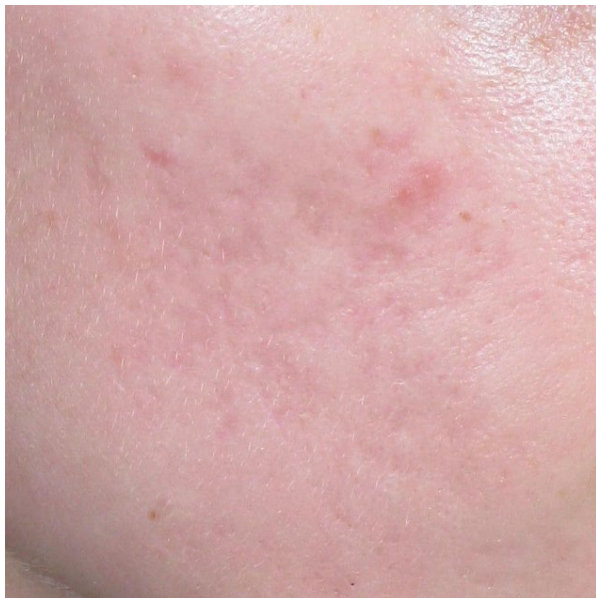### Grading key

- \*\*\*\*\* Treatment of choice
- \*\*\*\* Good option in most cases
- \*\*\* Good option in some cases often requiring combination with other modalities
- \*\* Acceptable but inferior to other options
- \* Not really a good option unless there is no other better alternative available



## Grade 2 scarring

Grade 2 scarring is mild, atrophic, or hypertrophic disease, which may not be obvious at a social distance (e.g., talking to someone conversationally in normal lighting) and is easily covered with makeup or by a beard or hair stubble (Figure 5). Ideally this degree of scarring should be matched to treatments with limited morbidity and risk.



**Figure 5.** Grade 2 post acne scars. Slightly atrophic scars but usually not visible at conversational distance ( $\geq 50$  cm from the observer).

## Manual skin needling or rolling

Manual skin needling comes in many forms. Rolling apparatus with embedded pins have given way to motorised pen shaped instruments that vibrate needles in and out of the skin or with stamping fixed pin designs. These techniques date back 20 years<sup>31</sup> injuring the skin and engendering a wound repair cascade that over several sessions will improve the quality of grade 2–3 atrophic skin scars.<sup>32,33</sup> This is a very well-tolerated procedure with low down time and morbidity for the patient with a low incidence of complications.<sup>34</sup> A small but well performed study illustrated the efficacy of skin needling as a treatment with clinical end points and microrelief silicon impression.<sup>34</sup>

### Key points

1. Manual skin needling appears to be a useful treatment for atrophic scars.
2. Multiple treatments are necessary.
3. Vascular lasers may be useful in other scar types.

## Nonablative nonfractionated resurfacing

This type of treatment describes the use of lasers and radiofrequency to bulk heat the dermis (rather than relying on fractionation) while cooling or otherwise to protect the epidermis.<sup>35</sup> These procedures have largely given way to fractionated devices but can be seen as the forerunners to similar technology given in a safer and more efficacious manner by fractionation.<sup>36</sup>

It has been of some use in milder forms of atrophic acne scarring but is limited in safety. It need not be limited to the face but if unintended epidermal injury ensues it may be slow to heal and result in complications.

These lasers use conducted heat from the chromophore, usually water, to produce a diffuse dermal injury, heating to  $>50^{\circ}\text{C}$  and inducing collagen remodelling. Repeated treatments are required, and durability of results remain largely unknown.

This technology seems to have acceptable patient satisfaction and perception of efficiency appearing reasonable<sup>37</sup>, although post-inflammatory hyperpigmentation may result, especially if blistering occurs.

### Key points

1. Non ablative resurfacing may be useful for mild atrophic scarring, but multiple treatments are necessary.
2. Fractionated equivalents may outstrip non-fractionated non-ablative technologies in terms of efficacy and safety.

## Microdermabrasion

Microdermabrasion is only useful for the mildest forms of scarring, often in the context of comedonal disease. It is often used in early pubertal acne or in grade 2 mildly atrophic disease.<sup>38,39</sup> Small crystals of aluminium oxide or other agents are expelled from a nozzle toward the skin, abrading it with a series of small lacerations, with the used crystals aspirated back from the skin surface and discarded.<sup>40</sup> Multiple treatments are needed and results in only mild improvement.<sup>41</sup> However, this is a safe treatment on or off the face with limited downtime which is well tolerated and comparatively inexpensive.

Its efficacy for the treatment of scarring is arguable<sup>42,43</sup> and much of whatever efficacy it may have may relate to changes in skin barrier function and consequent transepidermal water loss.<sup>44</sup>

### Key points

1. Microdermabrasion is possibly useful in the mildest forms of atrophic post acne scarring.
2. Multiple treatments are necessary.

## Volume treatments

Volume treatments may be used for grade 2 scarring, usually focal treatment with lower G prime hyaluronic fillers, or an approach that ignores the individual scars but concentrating instead on flooding the areas of scars to improve the underlying skin structure.<sup>45,46</sup>

There are permanent fillers for the treatment of post acne atrophic scars<sup>47</sup> although not everybody is comfortable with this approach.

One can also use tissue fillers if the individual scars are deep enough, and flooding the dermis with superficial dermal fillers is also a possibility. Although superficial dermal fillers are unproven in scarring, they have a rejuvenating effect on skin elasticity and dermal thickness.<sup>48</sup>

### Key points

1. Fillers probably have a limited role in the treatment of milder forms of atrophic acne scarring.

## Fractionated resurfacing

Since fractionated technologies are largely supplanting other resurfacing technologies, studies comparing fractionated technologies to resurfacing technologies and others comparing the available fractionated technologies are discussed here. An example of fractionated hybrid CO2 and 1570 nm laser treatment is shown in Figure 6.

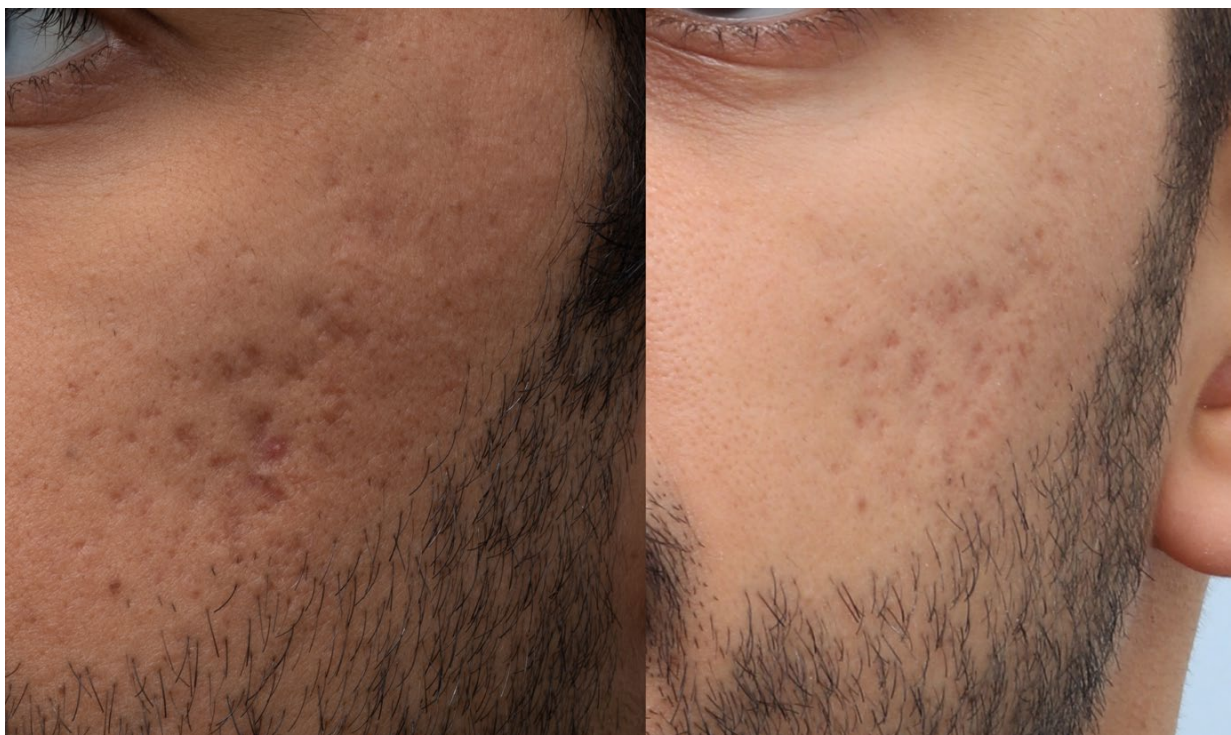## Fractionated laser versus placebo

In a within patient trial<sup>49</sup> similar sized areas on each side of the face were randomised to receive three sessions of fractionated CO2 laser at monthly intervals while the contralateral site received no treatment (placebo).

Three blinded physicians assessed outcomes on a 10-point scale. Improvement in skin texture and scar atrophy was seen in 12/12 participants with atrophic acne scars, from a baseline mean of 6.15 to a post treatment mean of 3.89 for skin texture and 5.72 for scar atrophy to 3.56 at six months ( $P < 0.0001$ ).

Subjectively, all participants reported a median satisfaction score of 4.5 at 6 months using a numerical scale from 0 (unsatisfied) to 10 (maximal satisfaction).

In another split face treatment,<sup>50</sup> 30 Chinese patients with atrophic acne scars on both cheeks received four sessions of fractionated 1550 nm Erbium glass (Er:Glass)



**Figure 6.** Before and after fractionated hybrid CO2 and 1570 nm laser



laser at 20-day intervals on one cheek whilst a control cream was applied to the other cheek three times daily. Clinical response and side effects were evaluated by a dermatologist three weeks after each treatment and 12 weeks after the last laser treatment. A patient treatment satisfaction questionnaire was performed at the end of treatment.

Mean scores for the acne scars decreased  $5.65 \pm 4.34$  after treatment for the treated side and  $1.23 \pm 3.41$  for the control side ( $P=0.0001$ ). Adverse effects were mild and transient.

Similar findings of efficacy over baseline using different parameters of Er:Glass 1550 nm lasers were seen in other studies.<sup>51,52</sup>

### Key points

1. Fractionated laser resurfacing is efficacious against placebo or non-treatment.
2. Most adverse events were mild or transient and manageable with hyperpigmentation being the most troublesome in those with higher Fitzpatrick skin types.
3. Fractionated lasers seem effective and useful for atrophic acne scarring.

## Fractionated laser versus fractionated radiofrequency

A parallel patient trial design<sup>53</sup> randomly divided 40 participants into two equal groups to receive either 1550 nm Er:Glass fractionated laser (Group A) or a fractionated radiofrequency device (Group B) over three sessions at 4-week intervals. 15/20 patients subjectively sustained average to excellent improvement in the appearance of acne scars. No statistically significant difference was reported between the two groups.

Ten percent of patients ( $n=2$ ) in the fractionated laser group developed post-inflammatory hyperpigmentation versus none in the radiofrequency group. There was shorter downtime and less pain in the radiofrequency group.

In the fractionated laser group, the mean ECCA grading scale was reduced from 74.25 to 55.50, a 25.0% decrease from baseline ( $P<0.001$ ). In the radiofrequency group, the mean decrease was from 68.75 to 56.00 ( $P<0.01$ ), an 18.6% reduction. There was no statistical difference noted between the two arms of treatment.

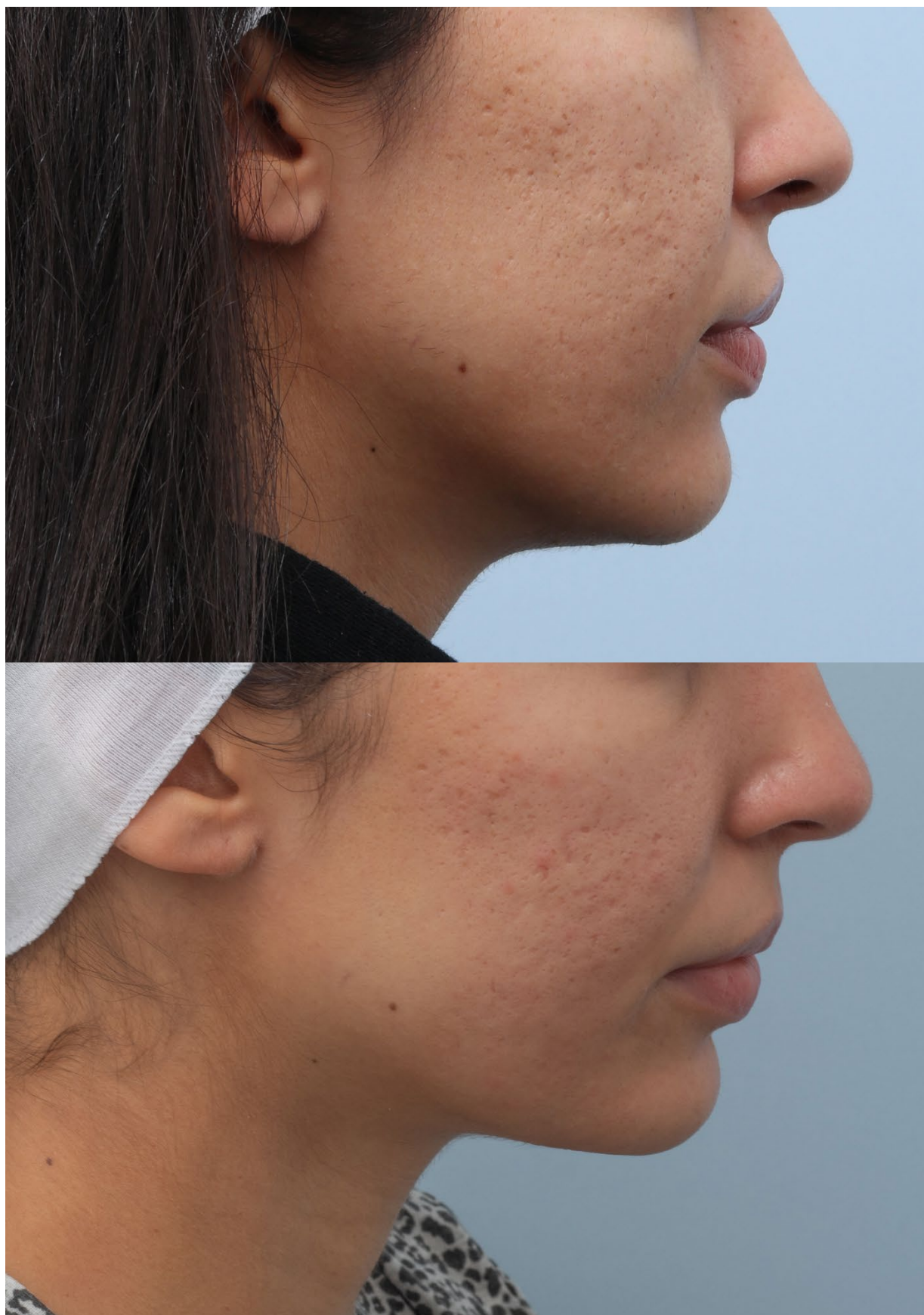Similar outcomes were seen in a within subject comparison of fractionated Erbium and fractionated bipolar radiofrequency in 20 Thai patients.<sup>54</sup> Treatment was delivered in a randomised fashion to one side of the face with the alternative technology to the other. After three treatments, 4 weeks apart, subjective analysis was similar with all patients completing the treatments. Patients rated both treatments as: moderately (2/4); very (3/4); or most (4/4) satisfied on a four-point scale. Objective scar improvement showed mean improvement after treatment of 2.86 and 2.70 for the fractionated Er:Glass and the fractionated bipolar radiofrequency devices, respectively.

Adverse events were similar although pain was statistically less with the radiofrequency device (mean difference = 1.85,  $P<0.001$ ), whilst the opposite was true for scab separation with the length of scab shedding treatment being longer with fractionated radiofrequency than with the fractionated laser.

Fractionated lasers and fractionated bipolar radiofrequency seem effective and useful for atrophic post acne scarring with an acceptable and similar adverse reaction rate. An example of nano-fractionated radiofrequency treatment is shown in Figure 7.

### Key points

1. Fractionated laser resurfacing is efficacious, as is bipolar fractionated radiofrequency.
2. There is no obvious superiority of either technology.
3. Adverse reactions are manageable with both technologies.
4. Hyperpigmentation may be more likely in fractionated laser resurfacing than radiofrequency.
5. Scab shedding may take longer with fractionated radiofrequency.



**Figure 7.** Before and after nano-fractionated radiofrequency treatment of grade 2 and 3 atrophic post acne scars



## Fractionated laser versus needling

In a 2015 study, 46 participants were randomised to receive either microneedling or fractionated 1340 nm laser or over three sessions at monthly intervals.<sup>55</sup> Subjectively, 65.0% of microneedling patients and 86.4% of laser patients noted improvement after the first treatment session, and 100% of participants in both groups noted improvement after the second session. Objective quantitative grading illustrated that the microneedling group improve from a mean of 14.9 to 10.85 and the laser group improved from 15.82 to 12.41 (both  $P < 0.001$ ). Boxcar scars seemed to improve more than rolling scars and both showed better improvement than ice pick scars. There was no statistical difference

between the two treatments in terms of efficacy, however, the laser group had more prolonged erythema and a higher incidence of post-inflammatory pigmentation.

### Key points

1. Needling appears to be a useful treatment for post acne scarring and may be a viable alternative to other fractionated resurfacing techniques.
2. Hyperpigmentation may not be as problematic with needling as compared to other fractionated technologies in skin of higher Fitzpatrick skin phototype.

**Table 3.** Treatment options for grade 2 atrophic scars

Examples of scars	Treatment plan
Mild rolling atrophic scars	<p><b>Surface</b></p> <p>Multiple treatments of one or more of the following:</p> <p>Fractionated ablative resurfacing*****</p> <p>Skin needling or rolling*****</p> <p>Fractionated radiofrequency (needling RF or nano-fractionated RF)*****</p> <p>Non-ablative fractionated resurfacing****</p> <p>Non-ablative non-fractionated resurfacing**</p> <p>Microdermabrasion*</p> <p><b>Volume</b></p> <p>Superficial tissue fillers**</p>

### Grading key

- \*\*\*\*\* Treatment of choice
- \*\*\*\* Good option in most cases
- \*\*\* Good option in some cases often requiring combination with other modalities
- \*\* Acceptable but inferior to other options
- \* Not really a good option unless there is no other better alternative available

## Conclusions

Scarring from past acne that is objectively less severe may still be distressing for patients. These types of scars may purely be surface colour issues (red, white, or brown) and may be temporary and have a positive natural history but not all these scars have such a benign outcome. They are sometimes easy to manage with lasers and other energy-based devices but sometimes are quite refractory to treatments or require a series of therapies to attain a result.

Texture related issues with mild atrophy will respond variably to treatment. Often surface treatments such as needling, microdermabrasion, or non-ablative full field technologies are sufficient. However, if the scars are at the more significant end of grade 2 scars, then fractionated technologies are important. All fractionated technologies appear useful.

## References

- Goodman GJ, Baron JA. Postacne scarring: a qualitative global scarring grading system. *Dermatol Surg*. 2006;32(12):1458–66.
- Fink B, Matts PJ. The effects of skin colour distribution and topography cues on the perception of female facial age and health. *JEADV* 2008;22:493–98.
- Samson N, Fink B, Matts PJ. Visible skin condition and perception of human facial appearance. *Int J Cosmet Sci*. 2010;32:167–84.
- Fink B, Matts PJ, Klingenberg H, Kuntze S, Weege B, Grammer K. Visual attention to variation in female facial skin color distribution. *J Cosmet Dermatol*. 2008;7(2):155–61.
- Chilicka K, Rusztowicz M, Szyguła R, Nowicka D. Methods for the Improvement of Acne Scars Used in Dermatology and Cosmetology: A Review. *J Clin Med*. 2022;11(10):2744.
- Spring LK, Krakowski AC, Alam M, Bhatia A, Brauer J, Cohen J, et al. Isotretinoin and Timing of Procedural Interventions: A Systematic Review With Consensus Recommendations. *JAMA Dermatol*. 2017;153(8):802–9.
- Xin Y, Zhang S, Deng Z, Zeng D, Li J, Zhang Y. Identification and verification immune-related regulatory network in acne. *Int Immunopharmacol*. 2020;89(Pt B):107083.
- Waldman A, Bolotin D, Arndt KA, Dover JS, Geronemus RG, Chapas A, et al. ASDS Guidelines Task Force: Consensus Recommendations Regarding the Safety of Lasers, Dermabrasion, Chemical Peels, Energy Devices, and Skin Surgery During and After Isotretinoin Use. *Dermatol Surg*. 2017;43(10):1249–62.
- Alster TS, Williams CM. Treatment of keloid sternotomy scars with 585 nm flashlamp-pumped pulsed-dye laser. *Lancet* 1995;345:1198–2000.
- Manuskiatti W, Fitzpatrick RE, Goldman MP. Energy density and numbers of treatment affect response of keloidal and hypertrophic sternotomy scars to the 585-nm flashlamp-pumped pulsed-dye laser. *J Am Acad Dermatol*. 2001;45:557–65.
- Sawcer D, Lee HR, Lowe NJ. Lasers and adjunctive treatments for facial scars: a review. *J Cutan Laser Ther*. 1999;1:77–85.
- Zaleski-Larsen LA, Fabi SG, McGraw T, Taylor M. Acne Scar Treatment: A Multimodality Approach Tailored to Scar Type. *Dermatol Surg*. 2016;42 Suppl 2:S139–49.
- Panchaprateep R, Munavalli G. Low-fluence 585 nm Q-switched Nd:YAG laser: a novel laser treatment for post-acne erythema. *Lasers Surg Med*. 2015;47:148–55.
- Dreno B, Khammari A, Orain N, Noray C, et al. ECCA grading scale: an original validated acne scar grading scale for clinical practice in dermatology. *Dermatology* 2007;214:46–51.
- Manuskiatti W, Fitzpatrick RE. Treatment response of keloidal and hypertrophic sternotomy scars: comparison among intralesional corticosteroid, 5-fluorouracil, and 585-nm flashlamp-pumped pulsed-dye laser treatments. *Arch Dermatol*. 2002;138:1149–55.
- Patel N, Clement M. Selective nonablative treatment of acne scarring with 585 nm flashlamp pulsed dye laser. *Dermatol Surg*. 2002;28:942–5.
- Glaich AS, Rahman Z, Goldberg LH, Friedman PM. Fractional resurfacing for the treatment of hypopigmented scars: a pilot study. *Dermatol Surg*. 2007;33:289–94; discussion 293–4.
- Alharbi MA. 1927 nm Thulium Laser Successfully Treats PostInflammatory Hyperpigmentation in Skin of Color. *Dermatol Res Pract*. 2021;2021:5560386.
- Yang CS, Huang YL, Cheng CY, Hu S, Chang SL, Lee MC. A Prospective Study of Fractionated Dual-Wavelength Picosecond Laser in Treating Acne Scar. *Lasers Surg Med*. 2020;52(8):735–42.
- Cohen BE, Brauer JA, Geronemus RG. Acne scarring: A review of available therapeutic lasers. *Lasers Surg Med*. 2016;48:95–115.
- Wang B, Wu Y, Luo YJ, Xu XG, Xu TH, Chen JZ, et al. Combination of intense pulsed light and fractional CO2 laser treatments for patients with acne with inflammatory and scarring lesions. *Clin Exp Dermatol*. 2013;38:344–51.
- Wat H, Wu DC, Rao J, Goldman MP. Application of intense pulsed light in the treatment of dermatologic disease: a systematic review. *Dermatol Surg*. 2014;40:359–77.
- Baugh EG, Anagu O, Kelly KM. Laser Treatment of Hypopigmentation in Scars: A Review. *Dermatol Surg*. 2022;48(2):201–6.
- Massaki AB, Fabi SG, Fitzpatrick R. Repigmentation of hypopigmented scars using an erbium-doped 1,550-nm fractionated laser and topical bimatoprost. *Dermatol Surg*. 2012;38:995–1001.
- Siadat AH, Rezaei R, Asilian A, Abtahi-Naeini B, Rakhshanpour M, Raei M, et al. Repigmentation of Hypopigmented Scars Using Combination of Fractionated Carbon Dioxide Laser with Topical Latanoprost Vs. Fractionated Carbon Dioxide Laser Alone. *Indian J Dermatol*. 2015;60:364–8.
- Roxo RF, Sarmiento DF, Kawalek AZ, Spencer JM, et al. Successful treatment of a hypochromic scar with manual dermabrasion: case report. *Dermatol Surg*. 2003;29:189–91.
- Camirand A, Doucet J. Needle dermabrasion. *Aesthetic Plast Surg*. 1997;21:48–51.
- Olsson MJ, Juhlin L. Long-term follow-up of leucoderma patients treated with transplants of autologous cultured melanocytes, ultrathin epidermal sheets and basal cell layer suspension. *Br J Dermatol*. 2002;147:893–904.
- Goodman GJ. An automated autologous cell transplantation method for the treatment of hypopigmented scarring. *Dermatol Surg*. 2008;34:578–81.
- Stoner ML, Wood FM. The treatment of hypopigmented lesions with cultured epithelial autograft. *J Burn Care Rehabil*. 2000;21 (1 Pt 1):50–4.
- Fernandes D. Percutaneous collagen induction: an alternative to laser resurfacing. *Aesthet Surg J*. 2002;22(3):307–9.
- Hou A, Cohen B, Haimovic A, Elbuluk N. Microneedling: A Comprehensive Review. *Dermatol Surg*. 2016 Oct 13. [Epub ahead of print]
- Abdel Hay R, Shalaby K, Zaher H, Hafez V, Chi CC, Dimitri S, et al. Interventions for acne scars. *Cochrane Database Syst Rev*. 2016 Apr 3;4:CD011946.
- Fabbrocini G, Fardella N, Monfrecola A, Proietti I, Innocenzi D. Acne scarring treatment using skin needling. *Clin Exp Dermatol*. 2009;34(8):874–9.
- Chan HH, Lam LK, Wong DS, Kono T, Trendell-Smith N. Use of 1,320 nm Nd:YAG laser for wrinkle reduction and the treatment of atrophic acne scarring in Asians. *Lasers Surg Med*. 2004;34(2):98–103.
- Min S, Park SY, Moon J, Kwon HH, Yoon JY, Suh DH. Comparison between Er:YAG laser and bipolar radiofrequency combined with infrared diode laser for the treatment of acne scars: Differential expression of fibrogenetic biomolecules may be associated with differences in efficacy between ablative and non-ablative laser treatment. *Lasers Surg Med*. 2016 Nov 2. doi: 10.1002/lsm.22607. [Epub ahead of print]

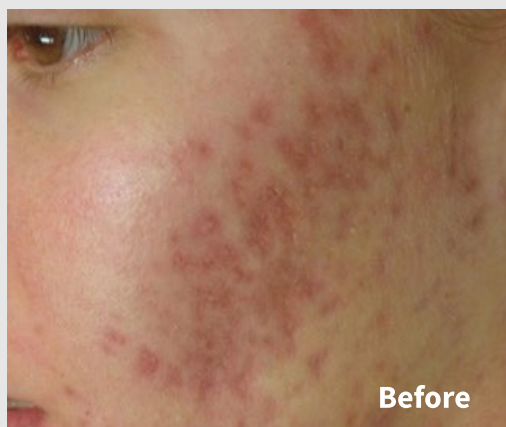

37. Bhatia AC, Dover JS, Arndt KA, Stewart B, Alam M. Patient satisfaction and reported long-term therapeutic efficacy associated with 1,320 nm Nd:YAG laser treatment of acne scarring and photoaging. *Dermatol Surg*. 2006;32:346-52.
38. Tsai RY, Wang CN, Chan HL. Aluminum oxide crystal microdermabrasion. A new technique for treating facial scarring. *Dermatol Surg*. 1995;21:539-42.
39. Fabbrocini G, Annunziata MC, D'Arco V, et al. Acne scars: pathogenesis, classification and treatment. *Dermatol Res Pract*. 2010;2010:893080.
40. Bhalla M, Thami GP. *Dermatol Surg*. 2006;32(6):809-14. Microdermabrasion: Reappraisal and brief review of literature.
41. Tam C, Khong J, Tam K, Vasilev R, Wu W, Hazany S. A Comprehensive Review of Non-Energy-Based Treatments for Atrophic Acne Scarring. *Clin Cosmet Investig Dermatol*. 2022;15:455-69.
42. Spencer JM. Microdermabrasion. *Am J Clin Dermatol*. 2005;6:89-92.
43. Freeman MS. Microdermabrasion. *Facial Plast Surg Clin North Am* 2001;9:257-66.
44. Rajan P, Grimes PE. Skin barrier changes induced by aluminium oxide and sodium chloride microdermabrasion. *Dermatol Surg*. 2002;28:390-3.
45. Sapra S, Stewart JA, Mraud K, Schupp R. A Canadian study of the use of poly-L-lactic acid dermal implant for the treatment of hill and valley acne scarring. *Dermatol Surg*. 2015;41(5):587-94.
46. Fife DJ. Commentary on a Canadian study of the use of poly-L-lactic Acid dermal implant for the treatment of hill and valley acne scarring. *Dermatol Surg*. 2015;41:595-6.
47. Joseph JH, Eaton LL, Cohen SR. Current Concepts in the Use of Bellafill. *Plast Reconstr Surg*. 2015;136(5 Suppl):171S-179S.
48. Kerscher M, Bayrhamme J. Rejuvenating influence of a stabilized hyaluronic acid-based gel of nonanimal origin on facial skin aging. *Dermatol Surg*. 2008;34:720-6.
49. Hedelund L, Haak CS, Togsverd-Bo K, Bogh MK, Bjerring P, Haedersdal M. Fractional CO<sub>2</sub> laser resurfacing for atrophic acne scars: a randomized controlled trial with blinded response evaluation. *Lasers Surg Med*. 2012;44:447-52.
50. Yang Q, Huang W, Qian H, Chen S, Ma L, Lu Z. Efficacy and safety of 1550-nm fractional laser in the treatment of acne scars in Chinese patients: A split-face comparative study. *J Cosmet Laser Ther*. 2016;18:312-6.
51. Alexis AF, Coley MK, Nijhawan RI, Luke JD, Shah SK, Argobi YA, et al. Nonablative Fractional Laser Resurfacing for Acne Scarring in Patients With Fitzpatrick Skin Phototypes IV-VI. *Dermatol Surg*. 2016;42:392-402.
52. Mahmoud BH, Srivastava D, Janiga JJ, Yang JJ, Lim HW, Ozog DM. Safety and efficacy of erbium-doped yttrium aluminum garnet fractionated laser for treatment of acne scars in type IV to VI skin. *Dermatol Surg*. 2010;36:602-9.
53. Chae WS, Seong JY, Jung HN, Kong SH, Kim MH, Suh HS, et al. Comparative study on efficacy and safety of 1550 nm Er:Glass fractional laser and fractional radiofrequency microneedle device for facial atrophic acne scar. *J Cosmet Dermatol*. 2015;14:100-6.
54. Rongsaard N, Rummaneethorn P. Comparison of a fractional bipolar radiofrequency device and a fractional erbium-doped glass 1,550-nm device for the treatment of atrophic acne scars: a randomized split-face clinical study. *Dermatol Surg*. 2014;40:14-21.
55. Cachafeiro T, Escobar G, Maldonado G, Cestari T, Corleta O. Comparison of Nonablative Fractional Erbium Laser 1,340 nm and Microneedling for the Treatment of Atrophic Acne Scars: A Randomized Clinical Trial. *Dermatol Surg*. 2016;42:232-41.

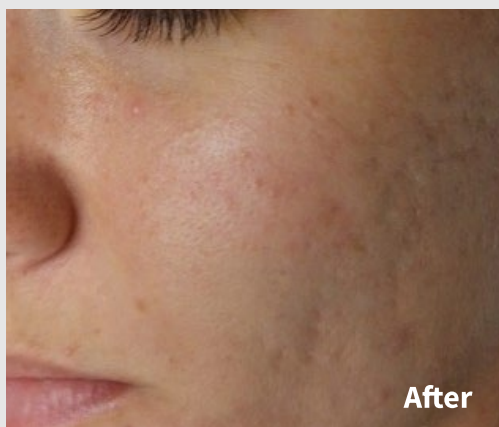# BRING THEIR INNER BEAUTY TO THE SURFACE

WITH SKINPEN® PRECISION

SkinPen®  
BY CROWN AESTHETICS



Before



After

Female Procedures: 6

\*Cases typical of results at Crown Aesthetics, individual results may vary.

## APPEARANCE OF ACNE SCARS\*

80%

At 1 month of treatment 80% of patients noticed improvement in how their acne scars looked.

90%

At 6 months 90% of patients noticed improvement.

0 1 2 3 4 5 6

Based upon a clinical study involving 41 patients conducted to support the safety and effectiveness of the SkinPen Precision System for the treatment of acne scars on the face. Patients were treated on day 1, day 30, and day 60, with follow-up visits at 1 month and 6 months after the final (day 60) treatment.\*

**This technologically advanced microneedling device will provide you and your patients with optimal efficacy and performance\*.**



 Scan me for your exclusive offer!\*\*

For medical practices only. This product is not available for purchase by the general public.

\*For complete clinical trial summary and information on how to use SkinPen Precision microneedling device, refer to the Instructions for Use.

\*\*Offer available for Australian and New Zealand subscribers only.



Exclusively distributed in Australia and New Zealand by Advanced Skin Technology

For more information please contact your AST Account Manager or contact:

AU customerservice@advskin.com.au | NZ customerservice@advskin.co.nz | AU 1800 648 851 | NZ 0800 238 754




# Classification and management of severe atrophic post acne scarring

Greg Goodman<sup>1,2</sup>

1. Monash University, Clayton, VIC, Australia
2. University College of London, London, UK

Correspondence: Professor Greg Goodman [ggg@div.net.au](mailto:ggg@div.net.au)

Disclosures: *none*



[CLICK IMAGE TO LINK TO VIDEO](#)

DURATION\_03:00

**OUTLINE:** Severely atrophic post acne scarring (Goodman Baron scale: grades 3–4) is characterised by rolling, ice pick and deep boxcars. These may occur with or without significant surface changes. Grade 3, or moderate scarring, can be treated with focal or general targeting of the presenting acne scar types. Fillers and subcision work well and are best combined with resurfacing techniques such as ablative and fractionated resurfacing, picosecond lasers and laser-assisted drug delivery, either contemporaneously or sequentially. For more severe grade 4 scars such as ice pick or deep punched out scars (deep boxcar), trichloroacetic acid chemical reconstruction of skin scars (TCA CROSS) or punch techniques, respectively, can be considered, either alone or in combination with resurfacing techniques. For broad atrophic areas, widespread subcision or dilute fillers are viable options alongside fat transfer.

**KEYWORDS:** scar, acne scar, CROSS, fillers, botulinum toxin

Goodman G. Classification and management of severe atrophic post acne scarring. *Opin Prog Cosmet Dermatol* 2022;2(3):17-30.

## Introduction

Severely atrophic post acne scarring comprises abnormally contoured volume-deficient disease. This may occur with or without surface changes of significance, however, patients often exhibit many scar types rather than just purely volume deficiency. This volume deficiency may exhibit the classical scar types of rolling, ice pick and deep boxcar types as well as multi fistulous tracks and gross volumetric loss. Movement may also contribute to the appearance of these scars as indrawing of the skin by attached mimetic muscles increases the apparent depth of the scars during expression.

Treatment of these scars may include surface treatment such as ablative and fractionated resurfacing as well as the newer developments of picosecond lasers and laser-assisted drug delivery.

Previously, we discussed assessment and management of milder forms of post acne scarring (Goodman Baron scale<sup>1</sup>: grades 1–2). This review will focus on treatment options for moderate and severe post acne scarring (Goodman Baron scale<sup>1</sup>: grades 3–4).

## Grade 3 post acne atrophic scarring

Using the Goodman and Baron qualitative post acne scarring scale we will begin by analysing grade 3 atrophic post acne scarring (Table 1). Grade 3 scars are moderately atrophic scarring obvious at conversational distance incorporating rolling and superficial boxcar type scarring (Figure 1).

Available treatments include surface active options such as non-fractionated and fractionated laser resurfacing, non-laser (e.g. radiofrequency) fractionated resurfacing, dermabrasion, and chemical peeling, and more recently pico lasers (both fractionated and non-fractionated), as well as laser assisted and device assisted drug delivery (Table 2).

Table 1. Grading scars according to burden of disease

Grade	Level of disease	Characteristics	Examples of scars
1	Macular disease	Red, brown, or white flat marks visible to patient or observer, irrespective of distance	Red, brown, or white flat marks
2	Mild disease	Mild atrophy that may not be obvious at social distances of $\geq 50$ cm and may be covered adequately by makeup or the normal shadow of shaved beard hair in males or normal body hair if extrafacial	Mild rolling scars either in isolation or in hills and valleys
3	Moderate disease	Moderate atrophic scarring that is obvious at social distances of $\geq 50$ cm and is not covered easily by makeup or the normal shadow of shaved beard hair in males or body hair if extrafacial, but is still able to be flattened by manual stretching of the skin	More significant rolling, shallow to deeper boxcar type scars
4	Severe disease	Severe atrophic scarring that is obvious at social distances of $\geq 50$ cm and is not covered easily by makeup or the normal shadow of shaved beard hair in males or body hair (if extrafacial), and is not able to be flattened by manual stretching of the skin	Punched out atrophic (deep boxcar), ice pick, bridges and tunnels, gross atrophy, dystrophic scars

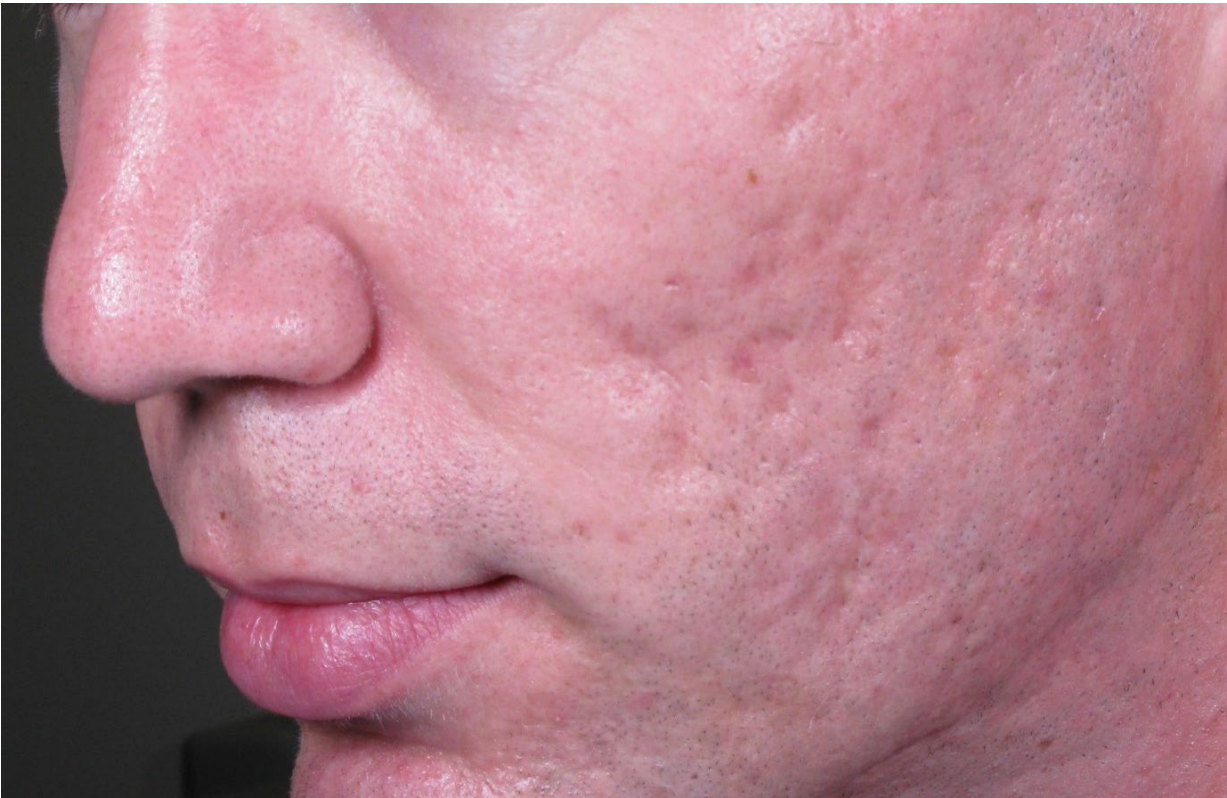

Figure 1. Grade 3 post acne scarring showing obvious atrophic scars visible from conversational distance that can be improved by stretching the scars



## Ablative laser therapy

### Non-fractionated laser skin resurfacing

Despite very little high-quality evidence of the value of full field laser skin resurfacing,<sup>2</sup> for nearly two decades, it had been considered the highest standard of care for the treatment of many post-acne and other types of scarring. This included rolling, superficial, and deep boxcar type scars. However, on its own it may not be nearly as effective as other therapies. Even for relatively shallow scarring it has probably been surpassed by fractionated devices.<sup>3,4</sup>

#### Key points

1. In the past ablative, non-fractionated (full-field) resurfacing was considered the best form of therapy in post acne scarring.
2. However, results were imperfect and morbidity significant.
3. Fractionated delivery has probably replaced non-fractionated technology in terms of efficacy, safety, and patient tolerability.

## Dermabrasion

Dermabrasion was the first major advance in the treatment of atrophic and traumatic scarring. It is probably at its best in treating grade 3 rolling scarring and can tighten the skin in an older patient with scarring.<sup>5</sup> Dermabrasion is similar to full field laser resurfacing in its morbidity but arguably less safe, so is now rarely used for this condition.

## Chemical peeling

Deeper peels may be employed for more severe scarring but need expertise and significant attention to safety aspects. A thorough understanding of endpoints and application techniques is essential. Several case series on the use of medium and deep chemical peeling in the treatment of atrophic scarring have attested to its utility.<sup>6</sup> One must always be willing to deal with post-inflammatory hyperpigmentation, but in skilled hands, even darker skinned patients have benefitted from medium and deep peels.

Interesting adaptations of chemical peels have included the “radio peel”<sup>7</sup> utilising trans-epidermal delivery of low strength trichloroacetic acid (TCA) (20%) and nano-fractionated radiofrequency, and the chemical reconstruction of skin scars (CROSS) technique discussed below under grade 4 scarring.

#### Key points

1. Dermabrasion has the same issues as full-field laser resurfacing and is currently rarely used.
2. Although historically useful and in the right hands still useful, medium and deep peels have been largely superseded by fractionated devices.
3. Peels can be made safer and more effective by combining lower strengths with other procedures (assisted drug delivery) or by focal delivery such as CROSS.

## Tissue fillers

If one considers the worldwide explosion in the use of hyaluronic acid tissue fillers, there is surprisingly a paucity of references to their use for indented scars,<sup>8,9</sup> and these comprise mostly of case reports or case series.<sup>10,11</sup> However, some prospective experimental design studies have been performed illustrating efficacy of hyaluronic acid in atrophic scarring.<sup>12,13</sup> They may be combined with other techniques to increase efficacy (Figure 2).<sup>14</sup>

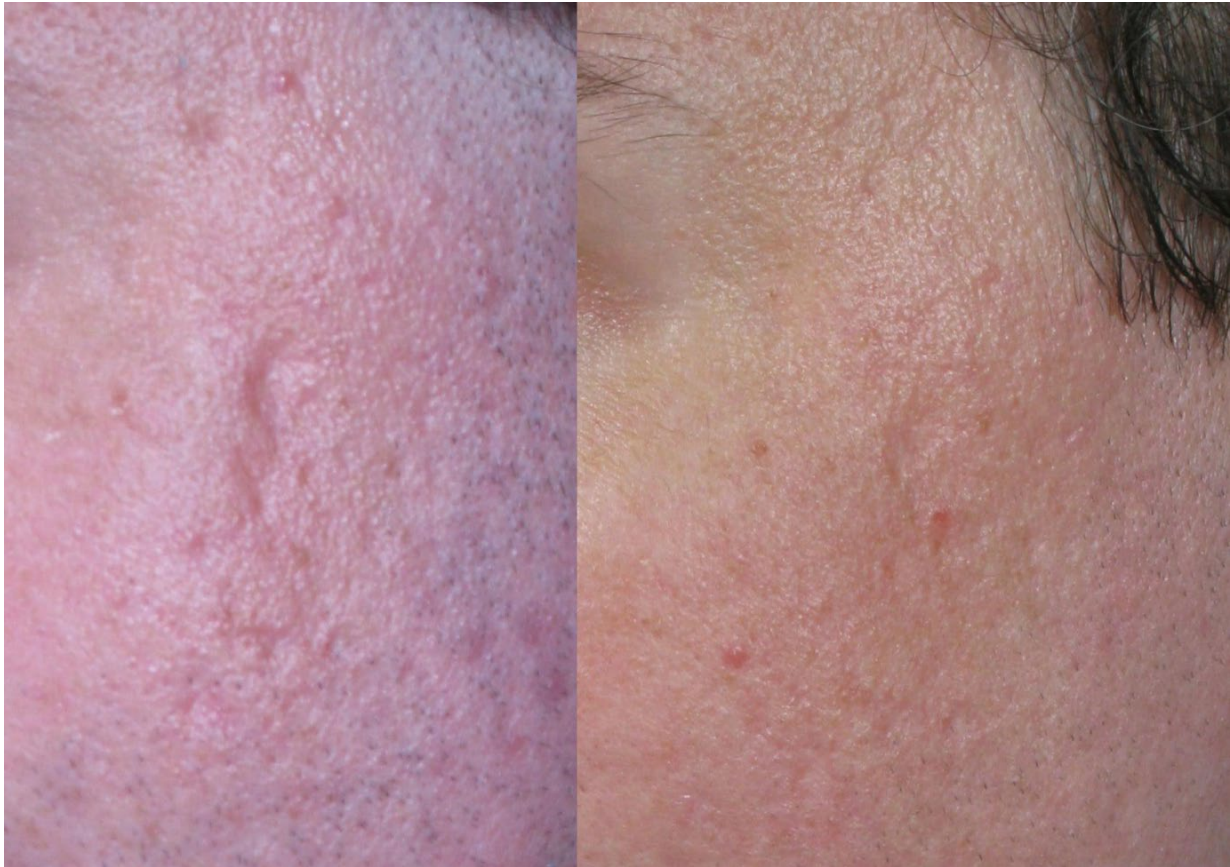Polymethylmethacrylate, a permanent filler, has been investigated in a large, controlled study of 147 patients but with a relatively short follow up period of 6 months. Using a validated scar scale, 64% of treated patients achieved success, versus 33% of control subjects. Only reversible adverse reactions were seen but one must stress the short-term study time frame.<sup>15</sup> The issues with the use of permanent agents (e.g. filler reactions, difficulty in removal, intravascular event) would tend to mitigate against their widespread use. However, more robust studies in the use of safer temporary agents would be welcome.

## Botulinum toxin

Botulinum toxin may be combined with fillers and may be synergistic in the treatment of scarring<sup>16</sup> where facial expressions increase the appearance of scarring. However, botulinum toxin is a more impressive agent in the treatment of hypertrophic scarring and keloids.

#### Key points

1. Fillers are useful in atrophic scarring, especially in isolated scars of rolling and boxcar types (Figure 3).
2. Morbidity is mild with fillers and neuromodulators, but more studies on their contribution when combined with other treatments and on their own would be useful.
3. Botulinum toxin may have a role in the treatment of atrophic scars.



**Figure 2.** Fillers and non-ablative 1550 nm laser resurfacing



Australasian  
Society of  
Cosmetic  
Dermatologists

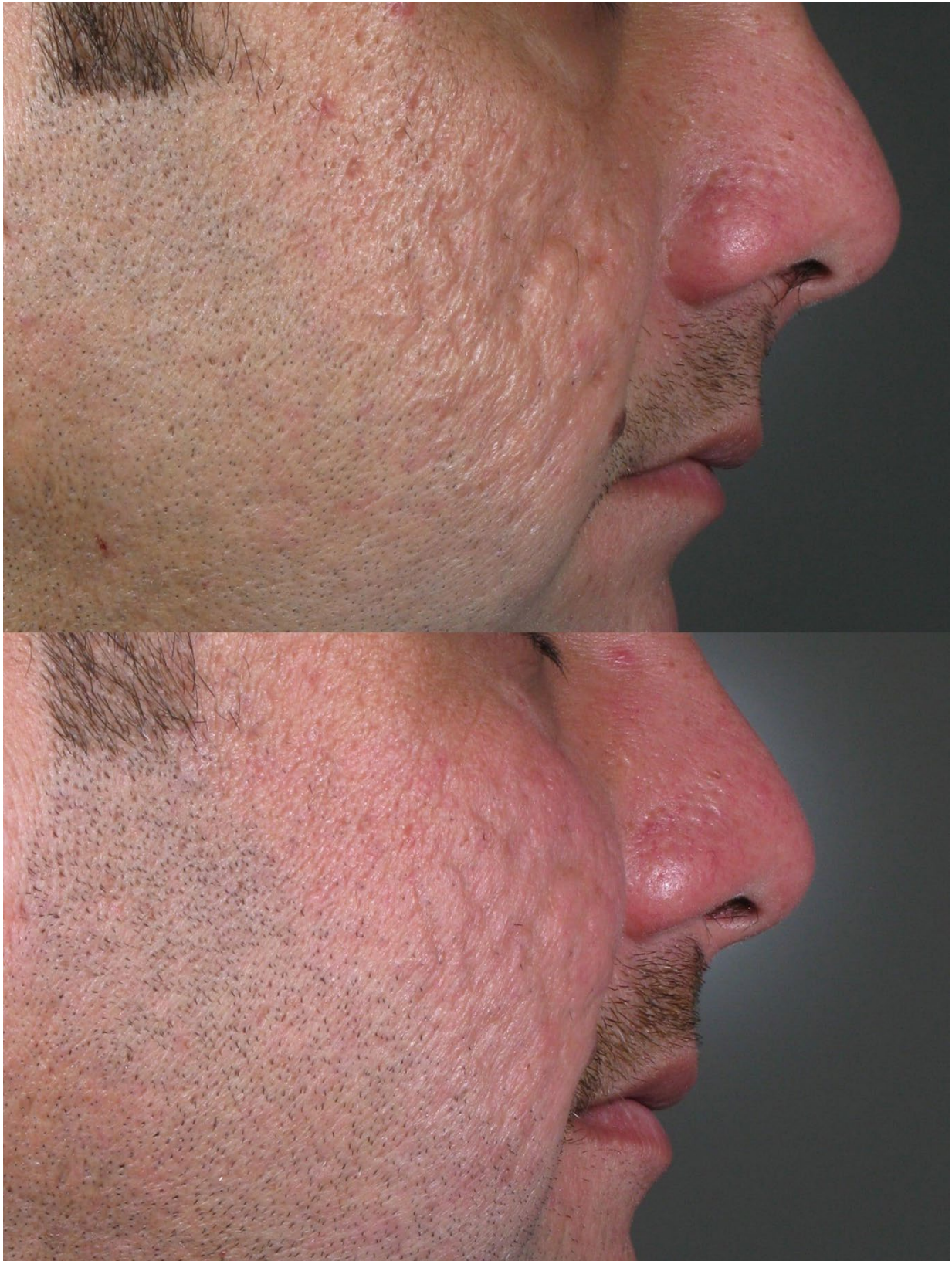ASCD Symposium 24 - 26 March 2023  
Crown Conference Centre

**SAVE THE DATE**



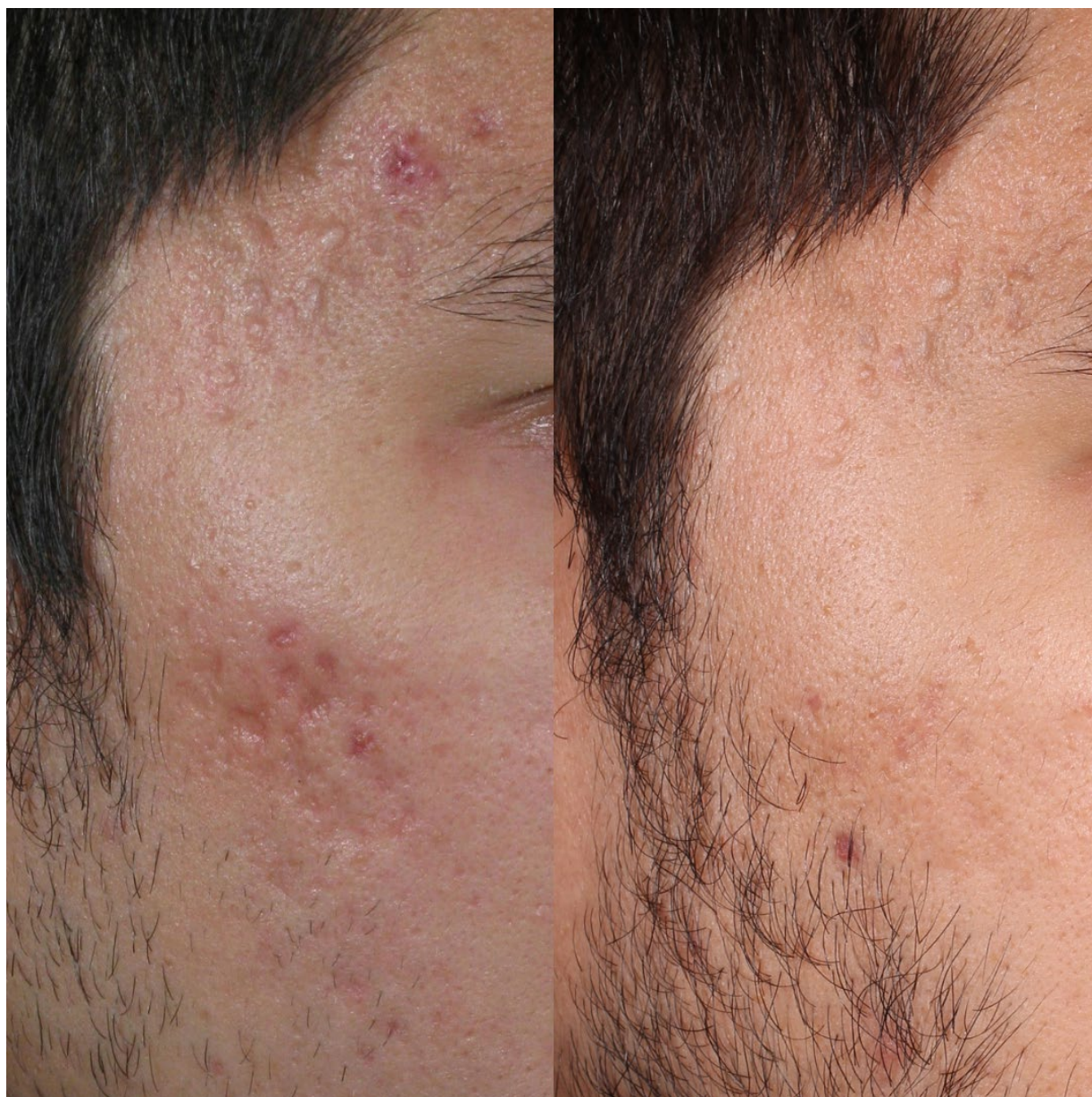**CLICK HERE TO FIND OUT MORE**  
[www.ascd.org.au](http://www.ascd.org.au)





**Figure 3.** Scarring treated with hyaluronic acid fillers. Note the biggest difference appears to be evident with more severe and more isolated scars





**Figure 4.** Subcision together with fractionated cautery and CROSS to rolling, ice pick and surface scarring

## Subcision

Subcision works by disrupting the attachments of atrophic acne scars, releasing the skin from the deeper structures. A search on subcision will detect close to 100 references attesting to its efficacy and unique place in dermatologic surgery and acne scarring since it was first described in 1995 (Figure 4).<sup>17</sup>

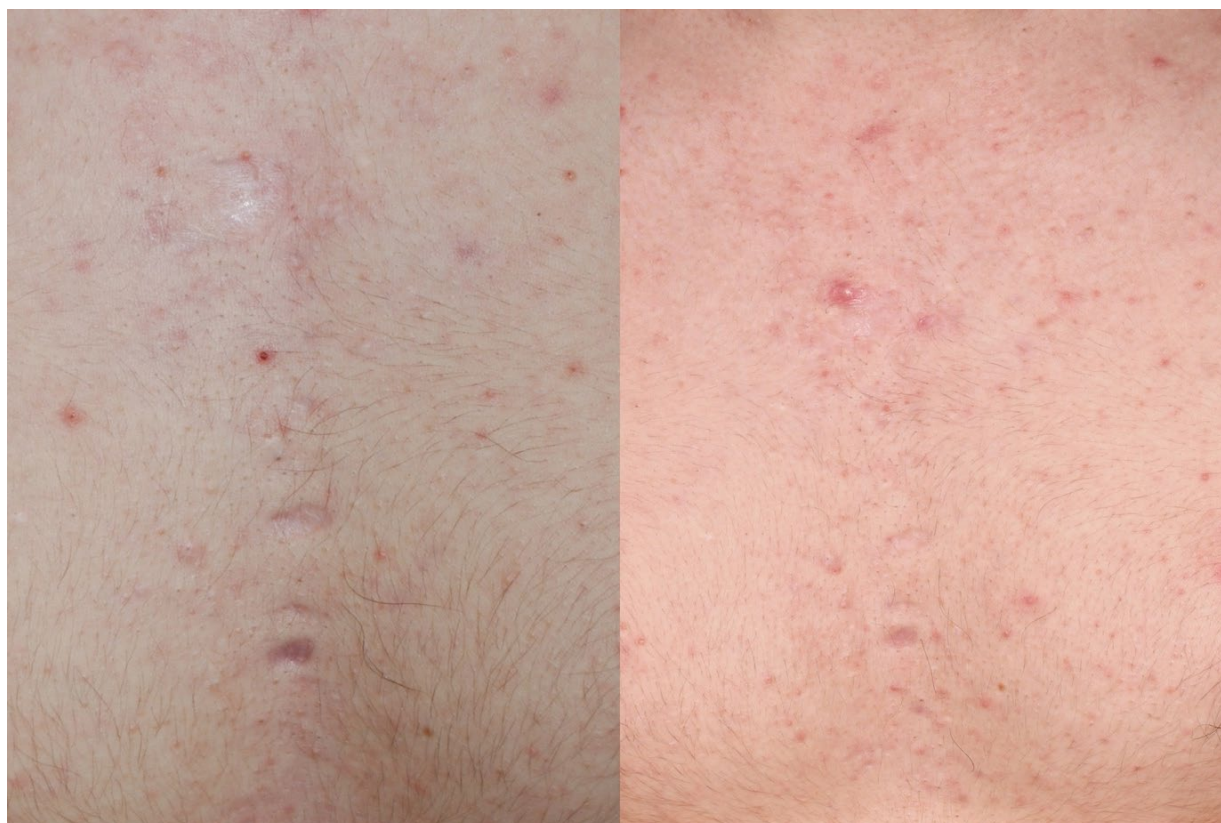Successive treatments producing further improvement<sup>18</sup> and combination with other techniques are probably the norm rather than the exception.<sup>19-20</sup>

Superficial insertion is suitable for small superficial scars, whereas deeper dermal undermining is performed for more severely bound down scars.

Bi-level subcision is useful for a combination of deep and superficial scarring.<sup>21</sup>

Comparative and combination studies have been performed including one studying 20 patients comparing 1-3 sessions of 100% TCA CROSS to scars on the left side of the face with subcision to scars on the right side.<sup>22</sup> This study indicated more improvement in rolling scars and less post-inflammatory pigmentation on the subcision side ( $P < 0.001$ ). This seems like an insufficient number of TCA treatments and TCA CROSS probably is best for ice pick scars.<sup>23</sup>

A combination study investigated 50 patients who received topical treatment, subcision, TCA 15% and needling in an alternating sequence.<sup>24</sup>



**Figure 5.** Chest atrophic scars treated with a combination of subcision and fillers

Retinoic acid 0.05% was used to prime the skin for a fortnight prior to a single subcision session using a 24-gauge needle. One day later, needling was performed, and retinoic acid immediately applied for 30 minutes after the procedure. Finally, two weeks later, TCA 15% was applied until speckled frosting occurred. This sequence of fortnightly needling and TCA peeling was continued until six cycles were completed. The Goodman Baron qualitative scale was used to assess improvement<sup>25</sup> allowing grading of patients into four grades of severity of scarring (grade 4 being the most severe, grade 1 the least).

Of the 16 patients with grade 4 scars, 62.5% improved to grade 2 and 37.5% improved to grade 3 scars. Of the 22 patients with grade 3 scars, 22.7% were left with no scars, and 9.1% improved to grade 1 and 68.2% improved to grade 2.

All patients with grade 2 scars were left with no scars. Patient satisfaction was understandably very high.

### Key points

1. Subcision is an important and efficacious treatment of atrophic post acne scarring.
2. Morbidity is mild and it may readily be combined with other therapies (Figure 5).

## Evolving technologies

Advancements in laser technologies may permit improvements in acne scarring to be separated from morbidity. Pico laser technology has been found not only to be useful for pigment but via its ability to produce dermal cavitation it may help to address texture issues including post acne scarring.<sup>26</sup> One group<sup>27</sup> investigated its use in post acne scarring in a single centre, 20 patient, prospective study. Patients received six treatments with a 755 nm picosecond laser with a spot size of 6 mm, fluence of 0.71 J/cm<sup>2</sup>, repetition rate of 5 Hz, and pulse width of 750 picoseconds using a diffractive lens array. Fitzpatrick skin types I-V were enrolled.

A three-dimensional analysis revealed a mean 24.3% improvement in scar volume, maintained at 1 (24.0%) and 3 (27.2%) months after treatment. Histologic analysis revealed elongation and increased density of elastic fibres, with an increase in dermal collagen and mucin.

Another study<sup>28</sup> investigated 20 patients utilising the quantitative and qualitative scales and showed improvement using 532 nm and 1064 nm fractionated pico laser. Quantitative improvement showed a drop from 15.2 to 10.6 and qualitative from 4.3 to 2.0.



Another evolving technology is the transepidermal delivery of substances utilising the microthermal zones, needle marks or ablated holes made by temporary fractionated technology or needling breaches in the epidermis. This has been mentioned above with needling and low concentration of TCA peeling (20%) acting similarly to more aggressive peels. The application of bimatoprost after fractionated laser for hypopigmentation also may hold promise although it probably does depend on just how dense the scarring is, working better in hypopigmentation alone than for dystrophic scarring. Treatment of atrophic scarring utilising similar concepts of percutaneous access provided by fractionated delivery has been studied with blinded photographic analysis after fractionated CO<sub>2</sub> and poly-L-lactic acid (PLLA) using the Modified Manchester Scar Scale.<sup>29</sup> The four blinded observers accurately identified 76 of the 80 “before” and “after” photographs agreeing that at the 3-month follow-up visit, 95% of the scars had improved by an average of 33%.

Needling in a split face study of platelet-rich plasma on one side and insulin (40 u/s Actrapid) on the other showed efficacy on both but with increased efficacy on the insulin treated side.<sup>30</sup>

A variation of this technique with apparent efficacy uses a hybrid CO<sub>2</sub> and 1570 nm laser and a sonophoresis handpiece to allow laser assisted drug delivery.

### Key points

1. Pico laser treatment appears to be an effective treatment for atrophic scarring with limited recovery time.
2. Transepidermal delivery of agents offers an exciting advance with a future for targeted dermal delivery.
3. Both these technologies offer significant improvement with the promise of less morbidity than previous treatments of similar efficacy.

**Table 2.** Treatment options for grade 3 atrophic scars

Examples of scars	Treatment plan
More significant rolling, shallow “box car”	<b>Surface</b>
	Fractionated resurfacing – ablative or non-ablative*****
	Medical skin rolling****
	Plasma skin resurfacing***
	Non-fractionated ablative lasers (CO <sub>2</sub> /Erbium)***
	<b>Volume</b>
	Focal dermal fillers if localised*****
	Consider volumetric, deeply placed hyaluronic acid,*** hydroxyapatite,*** or stimulatory agents such as polylactic acid*** if more generalised
	<b>Movement</b>
	Botulinum toxin to muscles in lower face in affected areas (chin, marionettes) or in sites (glabella, forehead) of maximal muscle movement***
	<b>Surgery</b>
	Subcision*****

### Grading key

- \*\*\*\*\* Treatment of choice
- \*\*\*\* Good option in most cases
- \*\*\* Good option in some cases often requiring combination with other modalities
- \*\* Acceptable but inferior to other options
- \* Not really a good option unless there is no other better alternative available



## Grade 4 post acne severe atrophic or hypertrophic scarring

This grade describes severely and abnormally contoured disease, usually non-distensible and includes severe atrophic or hypertrophic scarring obvious at conversational distance and not able to be flattened by manual stretching of the skin (Table 3, Figure 6).

## Trichloroacetic acid and phenol (CROSS technique)

Focal chemical peeling involving the use of TCA 60% to 100%, or phenol 88%, termed the CROSS technique, has raised interest in the treatment of smaller ice pick and poral type scars, which have always proved a challenge.

It has been found that three treatments with TCA 60% is inferior to six treatments with TCA 100%.<sup>31</sup> Phenol 88% seems a suitable alternative to TCA, either alone or in combination<sup>32</sup> with other techniques such as subcision and microneedling, and appear efficacious in the treatment of severe focal atrophic post acne scarring. It has been suggested that the occasional widening of scars seen with TCA is not seen when phenol 88% is substituted for high strength TCA.<sup>33</sup> In this technique the wounding agent is used very focally into small ice pick scarring with the intent to induce scarring but only intraluminal scarring initiating collapse of the internal diameter of the scar. Generally healing is rapid (less than 7 days) and multiple therapies are required. In higher Fitzpatrick skin types post-inflammatory pigmentation (PIH) is more common. Occasionally scars may widen but persistence in treatment is probably still likely to improve these scars.

### Key points

1. Focal TCA or phenol peeling (CROSS) is useful for treating ice pick scarring.

## Punch techniques (excision, grafting or elevation)

There are three punch treatments – punch excision, punch grafts and punch elevation – relevant for sharp walled scars, usually of 2 mm or greater.<sup>34</sup> Punch techniques all address a pitted scar using a straight-walled disposable or hair transplant punch that is slightly larger than the scar.

Punch excision is probably best used to treat sharp-walled or deep ice pick scars with dystrophic or white bases and for scars in hair-bearing areas presenting as a form of focal scarring alopecia. For punch excision, the punched material is removed and sutures are then

placed to oppose the wound, as per a normal excision.<sup>35</sup> Punch replacement grafting<sup>36</sup> is also used for scars with dystrophic bases but not in beard areas unless hair is also transplanted with the focal skin graft. The graft is often taken from the retroauricular area and is sized to be just a little bigger than the recipient site. Resurfacing may be performed 4–8 weeks later to flatten the grafts and blur the margins of the graft.

Punch elevation is a variation of other punch techniques, except that the scar is not discarded. This is only used if the scar base is acceptable as it will appear on the surface. The tissue cylinder is incised down to the level of the subcutaneous fat. The scar is then coaxled with gentle use of forceps to tease up the tissue until it reaches the same level as the surrounding skin (Figure 7).

The combination of fractionated CO2 laser in two sessions with punch elevations versus just the laser alone found significantly greater improvement when punch elevations were utilised in addition.<sup>37</sup>

All punch techniques are commonly used alongside other treatments.<sup>38</sup>

### Key points

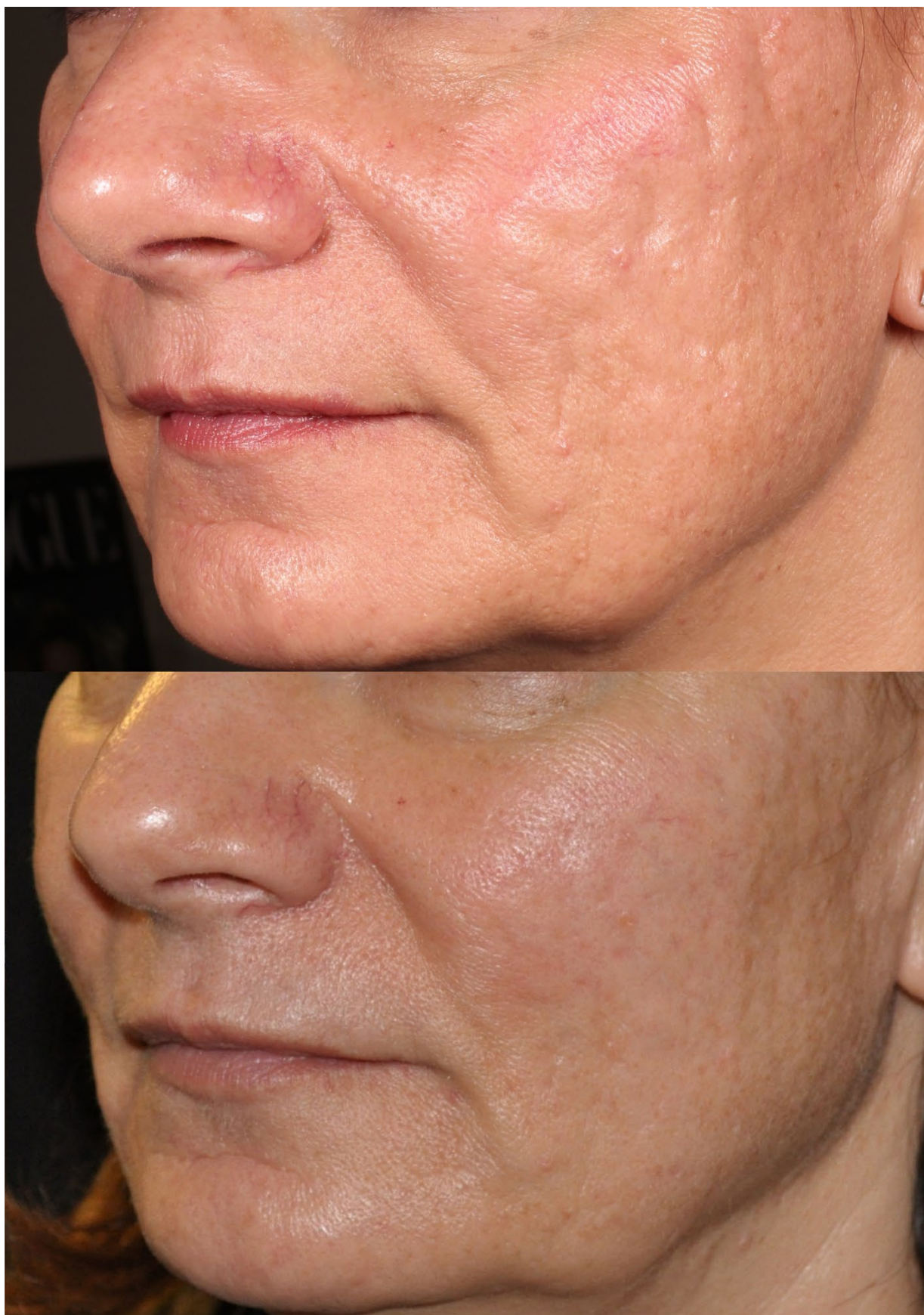1. Punch techniques including punch grafting, punch excision and closure, and punch elevation are valid techniques for deep boxcar type scars.
2. These techniques may be synergistic with resurfacing procedures.

## Fat transfer

For severely atrophic disease in which there is destruction of the deeper tissues, fat remains a valid replacement agent. It is easy to implant, inexpensive and readily available. It is not rejected, although it has a variable single treatment “take” rate and may need repeating. If the issue is widespread atrophic disease, then this technique remains a useful alternative (Figure 8).<sup>40</sup>

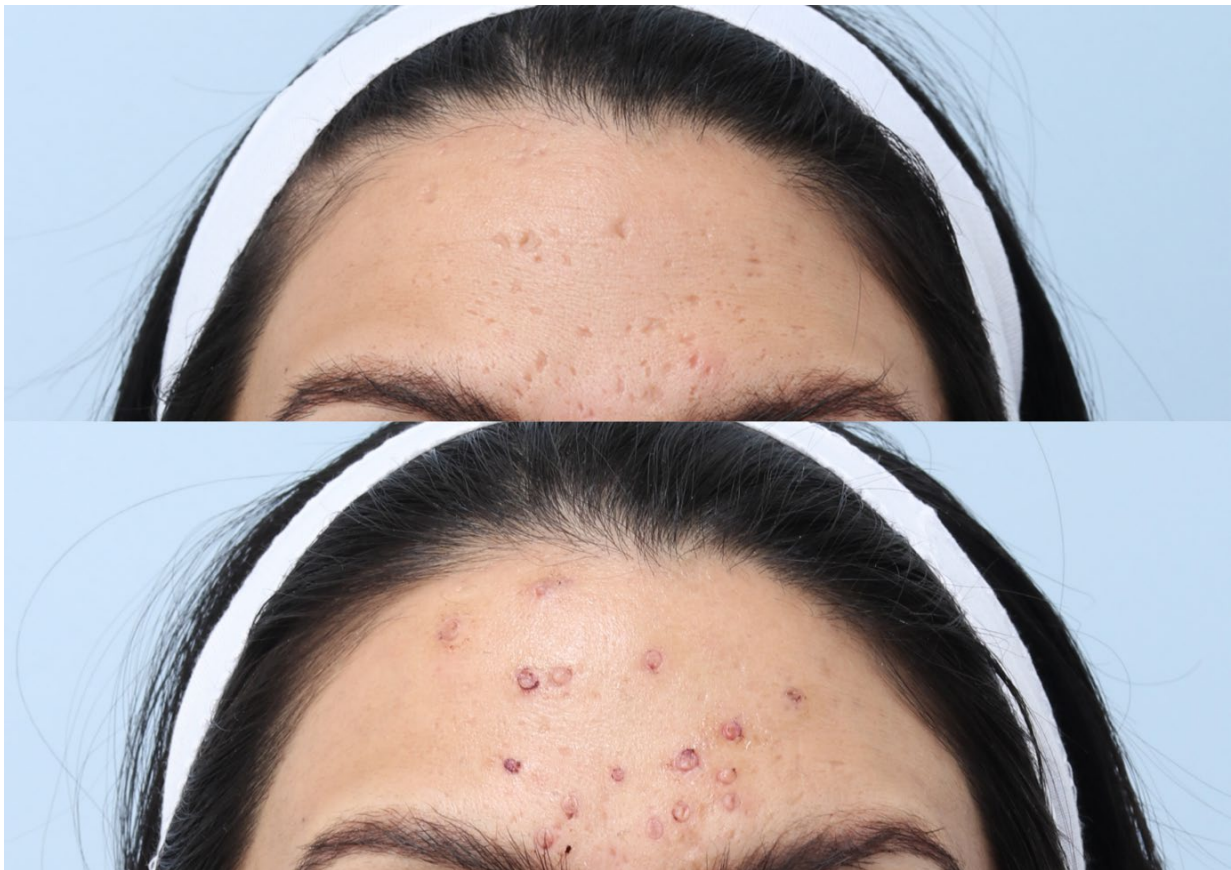Fat is making a resurgence especially alongside the use of platelet-rich plasma, stromal vascular fraction and stem cell technologies.<sup>39,40</sup>

Other non-autologous fillers are probably useful in restoring volume to deeply atrophic scars such as with PLLA.<sup>41</sup> Utilising a dilution technique for hyaluronic acid fillers, broad areas may be addressed with a small volume of hyaluronic acid product. Although this use was described for rejuvenation of the temple area<sup>42</sup> it may be extrapolated to underpinning volume loss from widespread acne scarring.

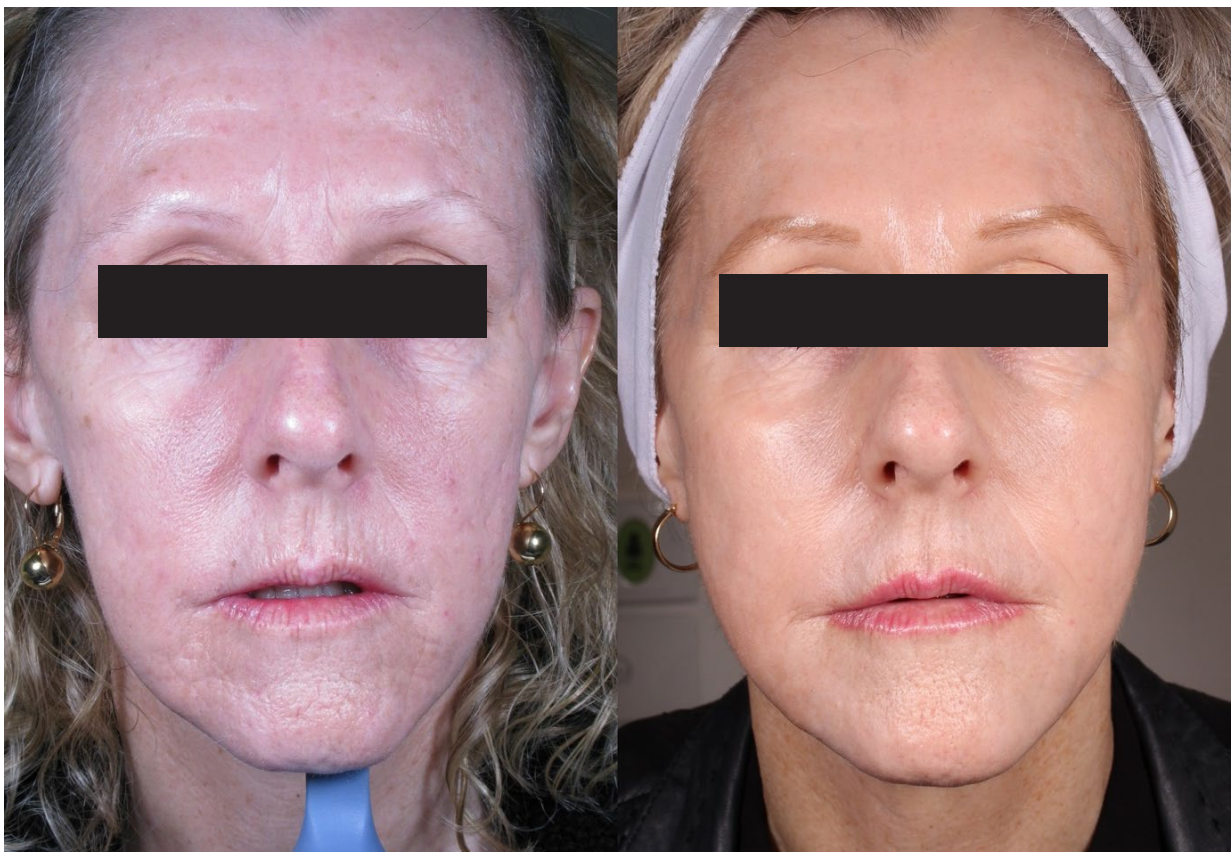

**Figure 6.** Grade 4 grossly atrophic acne scarring with improvement after tissue fillers and CO2 laser





**Figure 7.** Punch elevations of deep boxcar scars at baseline and at one week.



**Figure 8.** Severe post acne scarring and ageing related atrophic disease. Treatment with fat transfer laterally, hyaluronic acid medially and CO2 laser resurfacing.



## Key points

1. Fat transfer is still useful for severe atrophy associated with acne scarring.
2. Longevity and reproducibility issues may be aided by the addition of platelet-rich plasma and stem cells.
3. Other non-autologous fillers may have a role in addressing widespread areas of atrophy.

**Table 3.** Treatment options for grade 4 atrophic scars

Examples of scars	Treatment plan
<b>Punched out atrophic (deep boxcar), ice pick</b>	<b>Surface</b> TCA or phenol 88% (CROSS technique If numerous, deep and small)***** Fractionated resurfacing may be combined with CROSS*** If fewer and broader but still <4 mm in diameter, consider punch techniques (elevation, excision, or grafting) – see surgery (below), with or without subsequent fractionated or ablative resurfacing techniques
<b>Marked generalised atrophy</b>	<b>Volume</b> Fat transfer**** Volumetric filling with: hyaluronic acid**** hydroxyapatite*** stimulatory fillers such as polylactic acid*** (if fat or other fillers not feasible) Permanent fillers (e.g., PMMA)*
<b>Atrophy in areas of amplification by movement</b>	<b>Movement</b> Botulinum toxin often combined with fillers especially in lower face for atrophic disease***  <b>Surgery</b>
<b>Punched out scars (deep boxcar)</b>	Punch elevation if scar base is relatively normal***** Punch excision, punch grafting if scar base poor**** Excision of broader scars or ones with irregular or dystrophic bases***

## Grading key

- \*\*\*\*\* Treatment of choice
- \*\*\*\* Good option in most cases
- \*\*\* Good option in some cases often requiring combination with other modalities
- \*\* Acceptable but inferior to other options
- \* Not really a good option unless there is no other better alternative available

## Conclusion

For severe scarring (grades 3 and 4), several techniques are useful. Grade 3 scarring is well treated by focal or general attention to what has been termed rolling scars or shallow boxcar scars.

For rolling scars or shallow boxcar scars, generally fillers and subcision are best usually combined with resurfacing techniques either contemporaneously or sequentially.

For more severe grade 4 scars, when focal such as ice pick or deep punched out scars (deep boxcar), focal scar destruction (CROSS) or punch techniques are excellent either alone but usually in combination with resurfacing techniques. For broad areas of atrophy widespread subcision or dilute fillers are viable options alongside fat transfer.

## References

- Goodman GJ, Baron JA. Postacne scarring: a qualitative global scarring grading system. *Dermatol Surg*. 2006;32(12):1458–66.
- Jordan R, Cummins C, Burls A. Laser resurfacing of the skin for the improvement of facial acne scarring: a systematic review of the evidence. *Br J Dermatol*. 2000;142(3):413–23.
- Stulhofer Buzina D, Lipozenčić J, Bukvić Mokos Z, Ceović R, Kostović K. Ablative laser resurfacing: is it still the gold standard for facial rejuvenation? *Acta Dermatovenerol Croat*. 2010;18(3):190–4.
- Hantash BM, Gladstone HG. Current role of resurfacing lasers. *Ital Dermatol Venereol*. 2009;144:229–41.
- Goodman GJ. Dermabrasion Using Tumescence Anaesthesia. *J Dermatol Surg Oncol*. 1994;20:802–7.
- Al-Waiz MM, Al-Sharqi AI. Medium-depth chemical peels in the treatment of acne scars in dark-skinned individuals. *Dermatol Surg*. 2002;28:383–7.
- Artzi O, Cohen S, Verner I, Mehrabi JN, Naveh HP, Shoshani H, et al. Radio Peel-Synergism Between Nano-fractional Radiofrequency and 20% Trichloroacetic Acid Chemical Peeling. *Dermatol Surg*. 2019;45(5):711–7.
- Smith KC. Repair of acne scars with Dermicool-P35. *Aesthet Surg J*. 2009;29(3 Suppl):S16–8.
- Richards KN, Rashid RM. Twenty-four-month persistence of hyaluronic acid filler for an atrophic scar. *J Cosmetic Dermatol*. 2011;10(4):311–2.
- Goodman GJ, Van Den Broek A. The modified tower vertical filler technique for the treatment of post-acne scarring. *Australas J Dermatol*. 2016;57:19–23.
- Artzi O, Cohen S, Koren A, Niv R, Friedman O. Dual-plane hyaluronic acid treatment for atrophic acne scars. *J Cosmet Dermatol*. 2020;19(1):69–74.
- Dierickx C, Larsson MK, Blomster S. Effectiveness and Safety of Acne Scar Treatment With Nonanimal Stabilized Hyaluronic Acid Gel. *Dermatol Surg*. 2018;44 Suppl 1:S10–S18.
- Halachmi S, Ben Amitai D, Lapidot M. Treatment of acne scars with hyaluronic acid: an improved approach. *J Drugs Dermatol*. 2013;12(7):e121–3.
- Ebrahim HM, Nassar A, ElKashishy K, Artima AYM, Morsi HM. A combined approach of subcision with either cross-linked hyaluronic acid or threads in the treatment of atrophic acne scars. *J Cosmet Dermatol*. 2022;21(8):3334–42.
- Karnik J, Baumann L, Bruce S, Callender V, Cohen S, Grimes P, et al. A double-blind, randomized, multicenter, controlled trial of suspended polymethylmethacrylate microspheres for the correction of atrophic facial acne scars. *J Am Acad Dermatol*. 2014;71:77–83.
- Goodman GJ. The use of botulinum toxin as primary or adjunctive treatment for post acne and traumatic scarring. *J Cutan Aesthet Surg*. 2010;3:90–2.
- Orentreich DS. Subcutaneous incisionless (subcision) surgery for the correction of depressed scars and wrinkles. *Dermatol Surg*. 1995;21:543–9.
- Goodman GJ. Therapeutic undermining of scars (Subcision). *Australas J Dermatol*. 2001;42:114–7.
- Liu Y, Li Z, Hu J, Wang M, Qu C, Wu H, et al. Treatment of nasal depressed scars using micro-plasma radiofrequency technology combined with subcision. *J Cosmet Dermatol*. 2022;21(6):2458–62.
- Nilforoushzadeh MA, Heidari-Kharaji M, Fakhim T, Torkamaniha E, Nouri M, Rafiee S, et al. Endo-Radiofrequency subcision for acne scars treatment: A case series study. *J Cosmet Dermatol*. 2022 Jun 29. doi: 10.1111/jocd.15195. Epub ahead of print.
- Rullan PP, Olson R, Lee KC. A Combination Approach to Treating Acne Scars in All Skin Types: Carbolic Chemical Reconstruction of Skin Scars, Blunt Bi-level Cannula Subcision, and Microneedling-A Case Series. *J Clin Aesthet Dermatol*. 2020;13(5):19–23.
- Ramadan SA, El-Komy MH, Bassiouny DA, El-Tobshy SA. Subcision versus 100% trichloroacetic acid in the treatment of rolling acne scars. *Dermatol Surg*. 2011;37:626–33.
- Lee JB, Chung WG, Kwahck H, Lee KH. Focal treatment of acne scars with trichloroacetic acid: chemical reconstruction of skin scars method. *Dermatol Surg*. 2002;28:1017–21.
- Garg S, Baveja S. Combination therapy in the management of atrophic acne scars. *J Cutan Aesthet Surg*. 2014;7:18–23.
- Goodman GJ, Baron JA. Postacne scarring: a qualitative global scarring grading system. *Dermatol Surg*. 2006;32:1458–66.
- Haimovic A, Brauer JA, Cindy Bae YS, Geronemus RG. Safety of a picosecond laser with diffractive lens array (DLA) in the treatment of Fitzpatrick skin types IV to VI: A retrospective review. *J Am Acad Dermatol*. 2016;74:931–6.
- Brauer JA, Kazlouskaya V, Alabdulrazzaq H, Bae YS, Bernstein LJ, Anolik R, Heller PA, Geronemus RG. Use of a picosecond pulse duration laser with specialized optic for treatment of facial acne scarring. *JAMA Dermatol*. 2015;151:278–84.
- Yang CS, Huang YL, Cheng CY, Hu S, Chang SL, Lee MC. A Prospective Study of Fractionated Dual-Wavelength Picosecond Laser in Treating Acne Scar. *Lasers Surg Med*. 2020;52(8):735–42.
- Rkein A, Ozog D, Waibel JS. Treatment of atrophic scars with fractionated CO2 laser facilitating delivery of topically applied poly-L-lactic acid. *Dermatol Surg*. 2014;40:624–31.
- Pawar M, Singh M. Microneedling with autologous platelet-rich plasma versus microneedling with topical insulin in the treatment of postacne atrophic scars: A simultaneous split-face comparative study. *J Am Acad Dermatol*. 2021;84(3):810–1.
- Lee JB, Chung WG, Kwahck H, Lee KH. Focal treatment of acne scars with trichloroacetic acid: chemical reconstruction of skin scars method. *Dermatol Surg*. 2002;28(11):1017–21.

32. Rullan PP, Olson R, Lee KC. A Combination Approach to Treating Acne Scars in All Skin Types: Carbolic Chemical Reconstruction of Skin Scars, Blunt Bi-level Cannula Subcision, and Microneedling-A Case Series. *J Clin Aesthet Dermatol*. 2020;13(5):19-23.
33. Dalpizzol M, Weber MB, Mattiazzi AP, Manzoni AP. Comparative Study of the Use of Trichloroacetic Acid and Phenolic Acid in the Treatment of Atrophic-Type Acne Scars. *Dermatol Surg*. 2016;42(3):377-83.
34. Levy LL, Zeichner JA. Management of acne scarring, part II: a comparative review of non-laser-based, minimally invasive approaches. *Am J Clin Dermatol*. 2012;13(5):331-40.
35. Grevelink JM, White VR. Concurrent use of laser skin resurfacing and punch excision in the treatment of facial acne scarring. *Dermatol Surg*. 1998;24:527-30.
36. Solotoff S. Treatment for pitted acne scarring-postauricular punch grafts followed by dermabrasion. *J Dermatol Surg Oncol*. 1986;12:1079.
37. Faghihi G, Nouraei S, Asilian A, Keyvan S, Abtahi-Naeini B, Rakhshanpour M, et al. Efficacy of Punch Elevation Combined with Fractional Carbon Dioxide Laser Resurfacing in Facial Atrophic Acne Scarring: A Randomized Split-face Clinical Study. *Indian J Dermatol*. 2015;60:473-8.
38. Boen M, Jacob C. A Review and Update of Treatment Options Using the Acne Scar Classification System. *Dermatol Surg*. 2019;45(3):411-22.
39. James IB, Coleman SR, Rubin JP. Fat, Stem Cells, and Platelet-Rich Plasma. *Clin Plast Surg*. 2016;43:473-88.
40. Sasaki GH. The Safety and Efficacy of Cell-Assisted Fat Grafting to Traditional Fat Grafting in the Anterior Mid-Face: An Indirect Assessment by 3D Imaging. *Aesthetic Plast Surg*. 2015;39:833-46.
41. Beer K. A single-center, open-label study on the use of injectable poly-L-lactic acid for the treatment of moderate to severe scarring from acne or varicella. *Dermatol Surg*. 2007;33(Suppl 2):S159-67.
42. Lambros V. A technique for filling the temples with highly diluted hyaluronic acid: the "dilution solution". *Aesthet Surg J*. 2011;31(1):89-94.





In addition to the current Federal Government tax incentives supporting business investment, Allergan Aesthetics is proud to introduce an exclusive CoolSculpting Starter Package Offer.

THERE WILL NEVER BE A BETTER TIME TO PARTNER WITH THE WORLD'S #1 NON-INVASIVE BODY CONTOURING TECHNOLOGY<sup>1</sup>

24%

COOLSCULPTING  
STARTER PACKAGE  
DISCOUNT

for a limited time only

48

COMPLIMENTARY  
TREATMENT CYCLES

valued at AUD\$28 800:  
AUD\$600 per cycle



## THE COOLSCULPTING STARTER PACKAGE CONSISTS OF

A COOLSCULPTING CONTROL UNIT + YOUR CHOICE OF 2 TREATMENT APPLICATORS + 48 COMPLIMENTARY TREATMENT CYCLES

+ UP TO 60% OFF ADD ON COOLSCULPTING APPLICATOR & TREATMENT CARD BUNDLES

This Starter Package is not available in conjunction with any other promotions, offers or discounts.

**PLEASE CLICK HERE TO LEARN MORE ABOUT THE COOLSCULPTING STARTER PACKAGE**

Adverse events should be reported to: Australia - [AU-CoolSculpting@AbbVie.com](mailto:AU-CoolSculpting@AbbVie.com) or New Zealand - [NZ-CoolSculpting@AbbVie.com](mailto:NZ-CoolSculpting@AbbVie.com)

REFERENCES: 1. Medical Insight Inc. The Global Aesthetic Market Study; Version XIX. 2021. 2. Allergan, CoolSculpting System User Manual. BRZ-101-TUM-EN6-M. 3. Allergan, CoolSculpting Important Safety Information (ISI) November 2021. Available at: <https://www.coolsculpting.com/pdfs/CSC125713-v3-CoolSculpting-Important-Safety-Information.pdf> [Accessed August 2022].

During the procedure patients may experience sensations of pulling, tugging, mild pinching, intense cold, tingling, stinging, aching and cramping at the treatment site.<sup>2</sup> These sensations subside as the area becomes numb.<sup>2</sup> Following the procedure, typical side effects include redness, swelling, blanching, bruising, firmness, tingling, stinging, tenderness, cramping, aching, itching, skin sensitivity and numbness.<sup>2</sup> Numbness can persist for up to several weeks.<sup>2</sup> A sensation of fullness in the back of the throat may occur after submental treatment.<sup>2</sup> The following rare and very rare side effects<sup>2</sup> have the following reported rates (approximate occurrences per number of treatments): paradoxical hyperplasia (1/3000 [0.033%]); late-onset pain (1/6000 [0.017%]); severe pain (1/6000 [0.017%]); hyperpigmentation (1/1000 [0.009%]); freeze burn (1/15000 [0.007%]); treatment area demarcation (1/20000 [0.005%]); vasovagal symptoms (1/30000 [0.003%]); subcutaneous induration (1/30000 [0.003%]); cold panniculitis (1/60000 [0.002%]) and hernia (1/185000 [0.001%]). The CoolSculpting<sup>®</sup> procedure is not for everyone. Patients should not have the CoolSculpting<sup>®</sup> procedure if they suffer from cryoglobulinaemia, cold agglutinin disease or paroxysmal cold haemoglobinuria.<sup>2</sup> The device is not intended to cause weight loss or to treat obesity.<sup>2</sup> CoolSculpting<sup>®</sup> is not a weight loss procedure and should not replace a healthy diet and active lifestyle.

CoolSculpting<sup>®</sup>, and the Snowflake Design are trademarks of Zeltiq Aesthetics, Inc., an AbbVie Company. © 2022 AbbVie. All rights reserved. Allergan Australia Pty Ltd (Allergan Aesthetics, an AbbVie Company), Level 20, 177 Pacific Highway, North Sydney NSW 2060. ABN 85 000 612 831. Allergan New Zealand Limited (Allergan Aesthetics, an AbbVie Company), Auckland. NZBN 94 290 3212 0141. AU-CSC-220150 V1. DoP: August 2022

**Allergan  
Aesthetics**  
an AbbVie company


# Acne and acne scarring in skin of colour

Shi Yu Derek Lim<sup>1</sup>, Hazel H Oon<sup>1</sup>, Chee Leok Goh<sup>1</sup>

1. National Skin Centre, Singapore

Correspondence: Chee Leok Goh [clgoh@nsc.com.sg](mailto:clgoh@nsc.com.sg)

Disclosures: H.H.O. is a speaker, advisory board member and researcher for Galderma and Janssen. C.L.G. has received honorarium from Galderma and is a member of the La Roche-Posay Medical Advisory Board. No funding was received for this article.



[CLICK IMAGE TO LINK TO VIDEO](#)

DURATION\_03:01

**OUTLINE:** Acne vulgaris has a growing prevalence and sizeable impact among individuals with skin of colour. Key structural, functional, genetic and microbiome differences exist among individuals with skin of colour. This accounts for the diversity of clinical characteristics observed in this population, such as papular acne scars in Asian skin and post-inflammatory hyperpigmentation (PIH) in darker skin phototypes. The higher risk of skin irritation from topical acne creams and PIH following inflammatory acne in these patients must be carefully considered when treating acne and acne scars.

**KEYWORDS:** acne, acne scar, skin of colour, ethnicity, treatment, laser

Lim SYD, Oon HH, Goh CL. Acne and acne scarring in skin of colour. *Opin Prog Cosmet Dermatol* 2022;2(3):32-39.

## Introduction

The prevalence of acne vulgaris appears to be increasing among individuals with skin of colour. This has sizeable impact on the quality of life in these patients. Its prevalence in Asia varies widely from 1.9 per million in Central Asia to 44.3 per million in East Asia in 2019, increasing throughout Asia from 1990, and in fact doubling within South Asia during the intervening 29 years.<sup>1</sup> Seventeen Asian countries rank among the top tenth percentile globally for the annual percentage increase in disability-adjusted life years attributed to acne from 1990 to 2017.<sup>2</sup> In this review, we highlight the variations in skin phototypes, genetic factors and sociocultural practices that account for the unique challenges in the management of acne and associated scarring in skin of colour.

## Physiological differences in skin of colour

Key differences are known to exist among individuals with skin of colour, which explain some of the unique clinical characteristics that are observed in acne and its sequelae.

### Structural and functional differences

The degree of skin pigmentation in darker skin phototypes is a result of a higher proportion of

eumelanin as well as a greater proportion of larger, individually dispersed melanosomes and reduced degradation in the upper epidermal layers compared to those of white descent.<sup>3</sup> Pigmentary variations account for the higher incidence of post-inflammatory hyperpigmentation (PIH) observed in skin of colour.

Studies of structural and functional skin characteristics of different ethnic groups demonstrate weaker barrier properties with a low degree of maturation in East Asian skin, while lower levels of ceramides and stratum corneum trypsin like enzyme activity are found in African American skin. This is thought to account for increased skin sensitivity in East Asians, and a high prevalence of xerosis in African American skin.<sup>4</sup>

Within the dermis, individuals of African descent exhibit larger and more fibroblasts, with smaller and more closely stacked collagen fibre bundles compared to white individuals. Fewer elastic fibres are present. The papillary dermis contains more blood vessels and macrophages, which also appear larger than in white skin.<sup>5</sup> These differences within the dermis may explain why certain forms of scarring are more prevalent in skin of colour.

### Genetic differences

Genome-wide association studies have identified genetic susceptibility loci for severe acne vulgaris

in patients of different ethnicities, such as single-nucleotide polymorphisms within the DDB2 gene, implicated in androgen metabolism, in Han Chinese. These are involved at various pathogenic steps, such as androgen metabolism and wound healing and tissue remodelling.<sup>6</sup>

### Microbiome differences

Dysbiosis of the skin microbiome has been implicated in the pathogenesis of acne. Within the Chinese population, patients with acne have been found to have differences in the relative abundances of bacterial species, with a significant increase in the *Faecalibacterium*, *Klebsiella*, *Odoribacter* and *Bacteroides* genera among those with severe acne.<sup>7</sup> In a pilot study comparing acne-affected areas of nine Caucasian and nine Chinese women, microbiome analysis showed similar bacterial abundances between both populations. However, within Chinese skin, a higher abundance of *Novosphingobium* taxa was found, with downregulation of 11 bacterial metabolic pathways, some involved in skin redox balance, during the follicular phase of the menstrual cycle.<sup>8</sup> Further studies on a larger scale are needed to derive functional and microbiomic variations among acne-affected individuals of different skin type, and to investigate the significance of these findings.

## Clinical characteristics of acne in skin of colour

Comparisons of clinical acne and its sequelae among different ethnicities and skin phototypes highlight key differences such as a higher prevalence of inflammatory acne in Asians (Figures 1 and 2), and of overall clinical acne and hyperpigmentation in patients of African American and Hispanic origin.<sup>9</sup> We will discuss various unique clinical characteristics observed in skin of colour.

### Papular acne scars

Soft white papular acne scars, manifesting as hypopigmented or skin-coloured elevated papules most commonly occurring on the jawline, nose, and chin, have also been reported in Asian skin, though they are less commonly reported compared to other scar types. In a retrospective single-centre study involving 416 patients of skin phototypes III or IV with acne scarring, 11.1% of patients had papular acne scars, compared to 98.6% with atrophic scars and 12.7% with keloid scars. Histology from papular scars demonstrated dermal fibrosis and reduced elastic fibres.<sup>10</sup> Under-recognition of this clinical morphology may lead to misclassification as acne, closed comedones or pseudocysts, leading to inappropriate treatment.

### Keloid scars

Patients of skin phototype VI with acne have more frequent keloid scarring (Figure 3) over the chest,

back and jawline compared to those of skin phototype IV and V, with patients of African origin having a higher tendency to develop scars, regardless of skin phototype.<sup>11</sup> The average keloid incidence is estimated at 5–10% in the African population, compared to 0.1–1% in the Asian population and <0.1% in other populations.<sup>12</sup>

### Post-inflammatory hyperpigmentation

PIH is a common sequela of acne in individuals with darker skin phototypes, especially among Asians (Figure 4). A prospective study involving 324 individuals from seven different Asian countries consulting a dermatologist for acne found that 58.2% had PIH. The frequency of PIH was highest in Thailand (91.7%), followed by Japan (78.6%) and China (65.4%). The majority of subjects had mild to moderate acne (73.3%), and were of skin phototypes III or IV (86.0%). The most common location of PIH was the cheeks (81.2%), followed by mandible (52.2%) and forehead (48.0%). 65.2% reported PIH lasting for one year or more, and 22.3% five years or longer. 32.2% of subjects reported that PIH was more bothersome than the acne itself.<sup>13</sup>

Evaluating acne-related PIH is a challenge even amongst experts. The difficulty of clinically assessing and managing PIH is especially evident in the Asian population. There is significant variability in assessing the presence of PIH. In one report, variability in PIH diagnosis was greatest when active acne was present.<sup>14</sup> Erythema in darker skin tones is easily mistaken for PIH and vice versa. Hence it is important to use specific clinical criteria to improve accurate evaluation of PIH in skin of colour. Dermoscopy may help in demonstrating brown structureless areas and a brown reticular pattern in acne-induced PIH.<sup>15</sup>

### Pomade acne

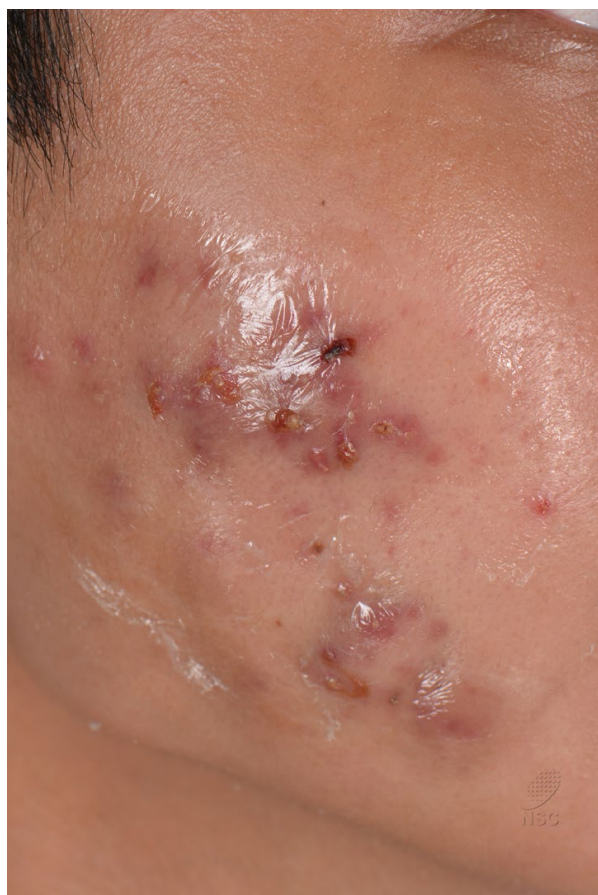In darker skinned individuals of African descent, the application of hair styling products may precipitate an acneiform eruption, characterized by numerous comedones and small papules, over the forehead and temples. Termed pomade acne, this has been reported to affect 70% of long-term users of hair-styling products of African descent with histological changes indistinguishable from acne vulgaris.<sup>16</sup>

## Treatment of acne in skin of colour

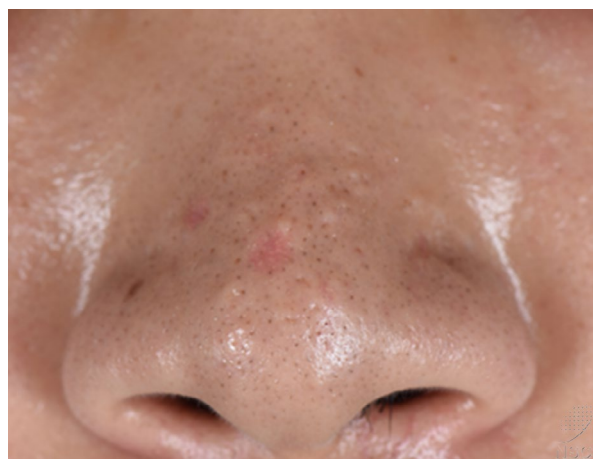The treatment algorithm of acne in all skin phototypes is largely similar.<sup>17</sup> However, care has to be taken to mitigate the potential for skin irritation in skin of colour.<sup>18</sup>

Topical retinoid therapy, while central to the management of acne, is also known to cause irritation and xerosis. There appears to be differences in racial susceptibility to skin irritation. Thus, there is a need to monitor the type and concentration of topical retinoid in some ethnic groups. The use of adapalene as

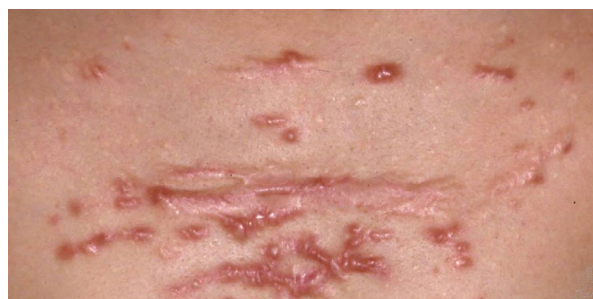



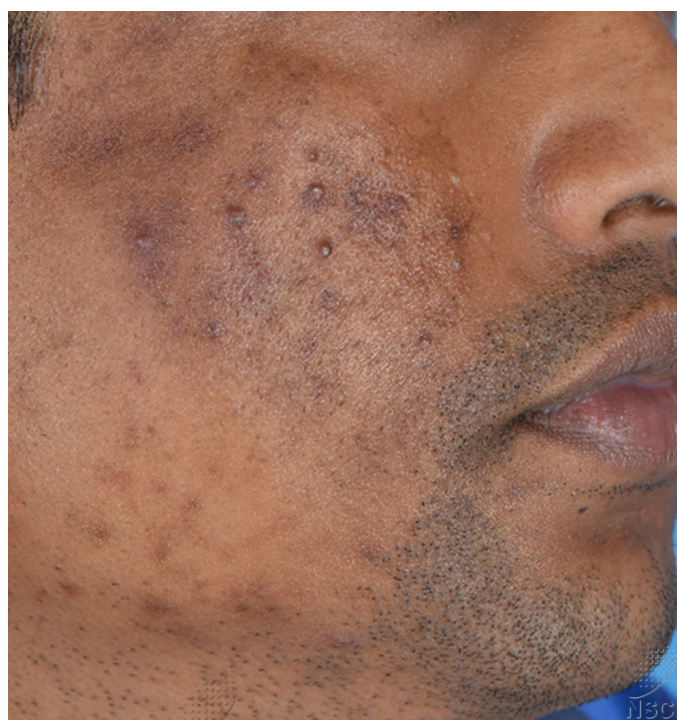**Figure 1.** Acne papules, pustules and discharging pseudocysts on the right cheek of this 26-year-old man of skin phototype III. Photograph courtesy of National Skin Centre, Singapore.



**Figure 2.** Acneiform papules on the nose of this patient of skin phototype IV. Photograph courtesy of National Skin Centre, Singapore.



**Figure 3.** Severe truncal acne in this man of skin phototype IV has led to keloidal scarring. Photograph courtesy of National Skin Centre, Singapore.



**Figure 4.** Severe post-inflammatory hyperpigmentation has resulted from facial acne in this man of skin phototype VI. Photograph courtesy of National Skin Centre, Singapore.

compared to tretinoin, concomitant use of moisturizer and initiating topical retinoid therapy with a reduced frequency e.g., alternate day dosing can help to improve tolerability and adherence.<sup>19,20</sup>

## Treatment and prevention of acne-related PIH in skin of colour

### Topical modalities

#### Retinoids

Topical retinoids, used either alone or in combination with topical antimicrobials or hydroquinone, have been found effective in several studies in reducing acne-related PIH in skin of colour.<sup>21</sup> However, strategies to mitigate irritation, as outlined above, are important to improve tolerability. Oral isotretinoin, when used for concomitant severe inflammatory acne vulgaris, also results in marked reduction in associated PIH.<sup>22</sup>

#### Azelaic acid

The twice-daily application of azelaic acid not only improves acne severity, but also PIH in skin of colour. In an open-label study involving 20 adults of skin phototypes V to VI, improvement in PIH was noted at four weeks of application, with further continued improvement observed up to 16 weeks of application. No serious adverse events were noted. Mild erythema and peeling, and moderate dryness were reported by a small minority of subjects.<sup>23</sup>

#### Hydroquinone

Hydroquinone, a tyrosinase inhibitor, is commonly used for the treatment of acne-related PIH, among other disorders of hyperpigmentation. It may be used alone or in combination with a corticosteroid and topical retinoid. The main concerns are the potential for ochronosis, reports of carcinogenesis in rodents with oral consumption, and in the combination form, risks of steroid-induced acne and atrophy.<sup>24</sup>

#### Chemical peels

Both Jessner's solution and salicylic acid 30% have been found effective in the reduction of acne-related PIH in a split-face study involving 36 patients of skin phototypes IV to V, with earlier reduction, but also one case of treatment-related PIH noted with the use of Jessner's solution.<sup>25</sup>

### Laser and other modalities

As topical applications only target epidermal PIH, deeper PIH within the dermis is recalcitrant to treatment and may require the use of other modalities for treatment. However, dermal PIH is more challenging to treat, and patients' expectations should be accordingly managed.

Low-power fractional carbon dioxide (CO<sub>2</sub>) laser and intradermal microinjections of tranexamic acid

have been both found efficacious in the treatment of acne-related PIH in patients of skin phototypes III to IV.<sup>26</sup> The use of the 1064 nm Q-switched neodymium-doped yttrium aluminium garnet (Nd:YAG) and 595 nm long pulsed dye lasers has also been described in a retrospective study comparing 34 female patients of skin phototypes III to V who underwent treatment with topical medication only, laser only or a combination of both topical and laser treatment for acne-related PIH. All three groups showed statistically significant improvement in PIH, with no difference among the groups.<sup>27</sup> While the use of oral tranexamic acid has been studied for disorders of hyperpigmentation such as melasma, Riehl's melanosis and laser-induced PIH, its use for acne-related PIH still requires further evaluation, and needs to be balanced against concerns of thromboembolism.

Acne-related PIH is a unique challenge in the management of acne in skin of colour. Given the available evidence, we suggest the first-line use of topical retinoids, as this also treats and prevents concomitant acne, with good tolerability. Azelaic acid should be considered as an alternative in females who are pregnant or planning pregnancy, or in those who are unable to tolerate retinoids. Hydroquinone cream can be used, after discussion on the potential risks. Other treatments such as chemical peels, tranexamic acid and laser treatments, including Q-switched lasers, may be considered for more recalcitrant cases, but require more in-depth counselling about their potential side effects, especially worsening of PIH with the former two options. Proper patient selection for treatment is important. Sun protection should be advised in all cases.

## Treatment of acne scars in skin of colour

Lasers and energy-based modalities, chemical treatments, microneedling and cold steel techniques are commonly employed for the treatment of acne scars in skin of colour. The occurrence of PIH is a key concern with the use of these modalities. We will discuss the evidence in the literature evaluating the safety and efficacy of various modes of treatment in skin of colour.

### Lasers and energy-based devices

Fractional lasers, employing the principle of fractional photothermolysis, have emerged as a popular treatment option for resurfacing of acne scars. Ablative and non-ablative fractional lasers are currently gold standard in the treatment of acne scars in skin of colour.

#### Fractional ablative lasers

In a single centre retrospective study involving 107 patients of skin phototypes III to IV who underwent 1-3 sessions of fractional CO<sub>2</sub> laser treatments for atrophic acne scars, a statistically significant reduction in acne scarring was noted after treatment, with the

most common adverse events being pain and erythema occurring in all patients, and PIH in 73.2% of patients, mostly lasting less than 3 months.<sup>28</sup> This highlights the potential for PIH with laser treatment in darker skin phototypes. The use of manual fractional technology, involving the use of manual interrupted laser “drilling” via the ultra-pulse CO<sub>2</sub> laser has also been found safe and effective in Asian patients with atrophic facial scars, including acne scars.<sup>29</sup>

The fractional ablative 2940 nm erbium-doped yttrium aluminium garnet (Er:YAG) laser has been utilized in a pinhole fashion to successfully treat papular scars on the chin and neck, with improvement in scar height and texture, and minimal healing time.<sup>30</sup>

#### **Fractional non-ablative lasers**

Improvement in acne scarring has been demonstrated in darker-skinned patients undergoing 1550 nm erbium-doped fractional non-ablative laser treatments, with no difference between higher and lower treatment densities. Most cases of hyperpigmentation were considered mild, with one patient's hyperpigmentation persisting to three months after the last treatment session.<sup>31</sup> The 755 nm alexandrite picosecond laser with diffractive lens array has also been found to be safe in skin of colour.<sup>32</sup>

A retrospective analysis involving 82 patients of skin phototypes III to V compared the treatment of acne scars, 45 with monthly fractional non-ablative 1550 nm erbium-doped lasers and 37 with 2-monthly fractional ablative CO<sub>2</sub> lasers. Similar efficacy was found in both groups, with 35% of patients attaining more than 50% improvement in the non-ablative group, compared to 37% of patients in the ablative group. A shorter recovery time was observed with the non-ablative laser. Incidences of transient PIH were similar between the two.<sup>33</sup>

#### **Radiofrequency treatments**

Fractional radiofrequency (FRF) is a form of non-ablative treatment used for the treatment of acne scars, among other conditions. The use of nanoneedles ensures targeted delivery of radiofrequency energy to the deep reticular dermis, without damage to more superficial structures, and has been shown to lead to regeneration of elastin and collagen. In a prospective, evaluator-blinded study, 25 subjects of skin phototypes III to IV with moderate to severe acne scarring received three monthly FRF treatments. The 23 subjects who completed the study had a significant reduction in cumulative acne scar volume, demonstrating continued improvement at six months of follow-up. All subjects reported pain and facial erythema, and only three (13.0%) developed hyperpigmentation after the procedure. The authors suggested reducing the energy density to further minimize the risk of PIH.<sup>34</sup>

Needle-guided intralesional radiofrequency ablation has also been proposed as an inexpensive, effective, and safe method of treating papular acne scars in darker skinned individuals. A series involving six young adult men of colour undergoing one to two sessions of treatment at four-weekly intervals demonstrated a 50% reduction in the total number of scars, with only mild transient PIH in two patients.<sup>35</sup>

Combining microneedle FRF and subablative fractional radiofrequency has been found effective in the treatment of atrophic acne scars in Asian skin. In a prospective study involving 20 subjects of skin phototype III to IV with moderate to severe atrophic facial acne scars, three combined microneedling and superficial FRF treatments, performed at four-weekly intervals, results demonstrated improvement in rolling, boxcar, and icepick scars. No serious adverse effects were observed.<sup>36</sup>

#### **Strategies for reduction and prevention of PIH with energy-based devices**

Given the propensity for PIH after the use of lasers and energy-based devices in skin of colour, many strategies have been employed to reduce its occurrence.<sup>37</sup> These can be divided into pre-treatment, treatment, and post-treatment measures.

Pre-treatment prophylaxis with topical agents such as glycolic acid, hydroquinone and retinoids has not been found effective in lighter skinned individuals.<sup>38</sup> The use of topical brimonidine was found to prevent PIH when used in a split-face method in two dark skinned individuals who underwent Q-switched laser treatments for melasma and solar lentigines.<sup>39, 40</sup> There are currently insufficient data to recommend the routine use of these topical agents before treatment.

Treatment parameters that can reduce the risk of PIH in skin of colour include the use of a non-ablative compared to ablative laser, lower fluences/treatment densities, longer pulse durations, adjunctive cooling, and a longer treatment interval.<sup>41, 42</sup>

Photoprotective measures, including sun avoidance, appropriate clothing and headwear, and broad-spectrum sunscreens of at least sun protection factor (SPF) 30 should be advised for at least three months after light-based procedures. The use of a broad-spectrum sunscreen with antioxidant agents has been found to reduce the incidence of PIH one week after ablative fractional CO<sub>2</sub> resurfacing in patients of skin phototype IV.<sup>43</sup> The short-term use of topical corticosteroids for two days post-procedurally has also been found effective in reducing the incidence of PIH in skin of colour.<sup>44</sup>

We recommend careful patient selection, modification of treatment parameters as above, as well as



post-operative counselling on photoprotection and short-term mid-potency topical corticosteroids to manage the risk of PIH with energy-based devices.

### Chemical modalities

Chemical peels are widely used for the treatment of acne scars. In a retrospective study evaluating 473 superficial chemical peels performed on 132 patients of skin phototypes III to VI, only 18 (3.8%) treatments resulted in side effects, of which 1.1% were short-term and 2.7% were long-term. The most frequent complications were prolonged crusting (2.3%), PIH (1.9%) and erythema (1.9%). Adverse events happened most frequently with lactic acid (14.3%), followed by 35% glycolic acid (6.48%) and 20% salicylic acid (5.17%), with a median duration lasting 4.5 weeks. Patients with skin phototype VI had a significantly higher odds of side effects (odds ratio 5.14). The authors concluded that superficial chemical peels have a relatively low complication rate when performed in a standardized manner in darker skin phototypes.<sup>45</sup>

Chemical reconstruction of skin scars (CROSS) involves the application of trichloroacetic acid at the base of atrophic scars. This leads to dermal remodelling and ameliorates scar appearance. In a single-centre study involving 62 patients of skin phototypes IV to V with atrophic acne scars, patients were treated with 70% trichloroacetic acid every two weeks for a total of four treatments. Of the 53 who completed the study, 66% had >50% clinical improvement three months after the last treatment. Twenty-one of the 62 patients recruited developed PIH, three of whom dropped out of the study due to PIH.<sup>46</sup>

Given that medium to deep chemical peels are required for optimal treatment of acne scars, we recommend lasers and energy-based devices over chemical modalities for darker skin phototypes. This is in view of the risk of hyperpigmentation, hypopigmentation, and other complications such as post-operative infections, scarring and pain.

### Microneedling

Microneedling entails the use of multiple fine needles to create punctures to the level of the papillary dermis, creating microwounds that lead to growth factor release, stimulating neocollagen and elastin formation.<sup>47</sup> In a prospective study involving 36 patients of skin phototype IV to V with moderate to severe atrophic facial acne scars, five monthly sessions of microneedling under topical anaesthesia resulted in significant improvement. The most common side effect was pain in 13 patients, followed by hyperpigmentation in five. However, three of the patients had severe hyperpigmentation and one developed severe tram-trek scarring, leading to withdrawal from the study.<sup>48</sup>

While microneedling offers promising results, the potential for hyperpigmentation and severe scarring causes us to be hesitant to recommend it as a first line treatment for the treatment of acne scars. We opine that laser devices offer greater control of treatment parameters to reduce such risks in skin of colour.

### Combination treatments

A combination treatment protocol, involving the use of four to six sessions of intense pulsed light (IPL) followed by two sessions of fractional CO<sub>2</sub> laser, was found to be effective and safe in a prospective study enrolling 37 Chinese patients with both inflammatory acne lesions and atrophic acne scars. IPL led to a significant improvement in inflammatory lesions, while the fractional CO<sub>2</sub> laser was effective in treating the atrophic acne scars. Most (83.8%) patients experienced transient erythema after IPL treatment, with no pigmentary changes noted. After fractional CO<sub>2</sub> laser treatment, all patients reported moderate pain, temporary erythema, oedema, and crusting. 37.8% of patients developed PIH, all resolving within three months.<sup>49</sup>

Combined treatment of rolling acne scars with a single session of 20% trichloroacetic acid peels, extensive subcision, and fractional ablative erbium laser under tumescent anaesthesia was found effective in a study involving 56 patients of skin phototypes IV to VI, with no permanent pigment alterations, hypertrophic or keloidal scarring after the procedure.<sup>50</sup>

### Conclusion

In evaluating and managing patients of colour, clinicians should be mindful that this population is diverse, with each racial group possessing unique physiological differences in their skin. These lead to a variety of clinical characteristics observed in acne and its sequelae. The potential for skin irritation and PIH when treating acne and acne scars must be carefully considered.

### References

1. Chen H, Zhang TC, Yin XL, Man JY, Yang XR, Lu M. Magnitude and temporal trend of acne vulgaris burden in 204 countries and territories from 1990 to 2019: an analysis from the Global Burden of Disease Study 2019. *Br J Dermatol*. 2022;186(4):673-83.
2. Urban K, Chu S, Giesey RL, Mehrmal S, Uppal P, Delost ME, et al. Burden of skin disease and associated socioeconomic status in Asia: A cross-sectional analysis from the Global Burden of Disease Study 1990-2017. *JAAD Int*. 2021;2:40-50.
3. Thong HY, Jee SH, Sun CC, Boissy RE. The patterns of melanosome distribution in keratinocytes of human skin as one determining factor of skin colour. *Br J Dermatol*. 2003;149(3):498-505.

4. Muizzuddin N, Hellemans L, Van Overloop L, Corstjens H, Declercq L, Maes D. Structural and functional differences in barrier properties of African American, Caucasian and East Asian skin. *J Dermatol Sci*. 2010;59(2):123-8.
5. Montagna W, Carlisle K. The architecture of black and white facial skin. *J Am Acad Dermatol*. 1991;24(6 Pt 1):929-37.
6. Common JEA, Barker JN, van Steensel MAM. What does acne genetics teach us about disease pathogenesis? *Br J Dermatol*. 2019;181(4):665-76.
7. Li CX, You ZX, Lin YX, Liu HY, Su J. Skin microbiome differences relate to the grade of acne vulgaris. *J Dermatol*. 2019;46(9):787-90.
8. Hrapovic N, Richard T, Messaraa C, Li X, Abbaspour A, Fabre S, et al. Clinical and metagenomic profiling of hormonal acne-prone skin in different populations. *J Cosmet Dermatol*. 2022 Jul 10. doi: 10.1111/jocd.15225.
9. Perkins AC, Cheng CE, Hillebrand GG, Miyamoto K, Kimball AB. Comparison of the epidemiology of acne vulgaris among Caucasian, Asian, Continental Indian and African American women. *J Eur Acad Dermatol Venereol*. 2011;25(9):1054-60.
10. Lee YJ, Lee CY, Shin MK. A Neglected Acne Scar Type: Papular Acne Scars and Their Correlations With Keloid Scars. *Dermatol Surg*. 2021;47(10):1347-51.
11. Morrone A, Franco G, Valenzano M, Fazio R, Maiani E, Pizzini E, et al. Clinical features of acne vulgaris in 444 patients with ethnic skin. *J Dermatol*. 2011;38(4):405-8.
12. Huang C, Wu Z, Du Y, Ogawa R. The Epidemiology of Keloids. In: Luc T  ot TAM, Esther Middelkoop, Gerd G. Gauglitz, editor. *Textbook on Scar Management*. Switzerland: Springer; 2021. p. 30-1.
13. Abad-Casintahan F, Chow SK, Goh CL, Kubba R, Hayashi N, Noppakun N, et al. Frequency and characteristics of acne-related post-inflammatory hyperpigmentation. *J Dermatol*. 2016;43(7):826-8.
14. Goh CL, Abad-Casintahan F, Chow SK, Kubba R, Miyachi Y, Noppakun N, et al. Evaluating acne-related post-inflammatory hyperpigmentation is a challenge even amongst experts. *J Dermatol*. 2014;41(12):1106-8.
15. Amatya B. Evaluation of Dermoscopic Features in Facial Melanosis with Wood Lamp Examination. *Dermatol Pract Concept*. 2022;12(1):e2022030.
16. Plewig G, Fulton JE, Kligman AM. Pomade acne. *Arch Dermatol*. 1970;101(5):580-4.
17. Oon HH, Wong SN, Aw DCW, Cheong WK, Goh CL, Tan HH. Acne Management Guidelines by the Dermatological Society of Singapore. *J Clin Aesthet Dermatol*. 2019;12(7):34-50.
18. Alexis AF, Woolery-Lloyd H, Williams K, Andriessen A, Callender VD, Kang S, et al. Racial/Ethnic Variations in Acne: Implications for Treatment and Skin Care Recommendations for Acne Patients With Skin of Color. *J Drugs Dermatol*. 2021;20(7):716-25.
19. Goh CL, Tang MB, Briantais P, Kaoukhov A, Soto P. Adapalene gel 0.1% is better tolerated than tretinoin gel 0.025% among healthy volunteers of various ethnic origins. *J Dermatolog Treat*. 2009;20(5):282-8.
20. Hayashi N, Kawashima M. Study of the usefulness of moisturizers on adherence of acne patients treated with adapalene. *J Dermatol*. 2014;41(7):592-7.
21. Callender VD, Baldwin H, Cook-Bolden FE, Alexis AF, Stein Gold L, Guenin E. Effects of Topical Retinoids on Acne and Post-inflammatory Hyperpigmentation in Patients with Skin of Color: A Clinical Review and Implications for Practice. *Am J Clin Dermatol*. 2022;23(1):69-81.
22. Winhoven SM, Ahmed I, Owen CM, Lear JT. Postinflammatory hyperpigmentation in an Asian patient: a dramatic response to oral isotretinoin (13-cis-retinoic acid). *Br J Dermatol*. 2005;152(2):368-9.
23. Kircik LH. Efficacy and safety of azelaic acid (AzA) gel 15% in the treatment of post-inflammatory hyperpigmentation and acne: a 16-week, baseline-controlled study. *J Drugs Dermatol*. 2011;10(6):586-90.
24. Chandra M, Levitt J, Pensabene CA. Hydroquinone therapy for post-inflammatory hyperpigmentation secondary to acne: not just prescribable by dermatologists. *Acta Derm Venereol*. 2012;92(3):232-5.
25. How KN, Lim PY, Wan Ahmad Kammal WSL, Shamsudin N. Efficacy and safety of Jessner's solution peel in comparison with salicylic acid 30% peel in the management of patients with acne vulgaris and postacne hyperpigmentation with skin of color: a randomized, double-blinded, split-face, controlled trial. *Int J Dermatol*. 2020;59(7):804-12.
26. Tawfic SO, Abdel Hay R, Salim H, Elmasry MF. Tranexamic acid versus fractional carbon dioxide laser in post-acne hyperpigmentation. *Dermatol Ther*. 2021;34(6):e15103.
27. Ho SG, Yeung CK, Chan NP, Shek SY, Kono T, Chan HH. A retrospective analysis of the management of acne post-inflammatory hyperpigmentation using topical treatment, laser treatment, or combination topical and laser treatments in oriental patients. *Lasers Surg Med*. 2011;43(1):1-7.
28. Fang F, Yang H, Liu X, Ding H, Yang Y, Ge Y, et al. Treatment of acne scars with fractional carbon dioxide laser in Asians: a retrospective study to search for predicting factors associated with efficacy. *Lasers Med Sci*. 2022;37(6):2623-7.
29. Jin W, Li Z, Jin Z, Jin C. A novel technique for treating atrophic facial scars in Asians using ultra-pulse CO2 laser. *J Cosmet Dermatol*. 2020;19(5):1099-104.
30. Lee SJ, Kim JM, Kim YK, Seo SJ, Park KY. The pinhole method using an erbium: YAG laser for the treatment of papular acne scars. *Dermatol Ther*. 2017;30(5).
31. Alexis AF, Coley MK, Nijhawan RI, Luke JD, Shah SK, Argobi YA, et al. Nonablative Fractional Laser Resurfacing for Acne Scarring in Patients With Fitzpatrick Skin Phototypes IV-VI. *Dermatol Surg*. 2016;42(3):392-402.
32. Haimovic A, Brauer JA, Cindy Bae YS, Geronemus RG. Safety of a picosecond laser with diffractive lens array (DLA) in the treatment of Fitzpatrick skin types IV to VI: A retrospective review. *J Am Acad Dermatol*. 2016;74(5):931-6.
33. Alajlan AM, Alsuwaidan SN. Acne scars in ethnic skin treated with both non-ablative fractional 1550 nm and ablative fractional CO2 lasers: comparative retrospective analysis with recommended guidelines. *Lasers Surg Med*. 2011;43(8):787-91.
34. Nitayavardhana S, Wanitphakdeedecha R, Ng JNC, Eimpunth S, Manuskiatti W. The efficacy and safety of fractional radiofrequency nanoneedle system in the treatment of atrophic acne scars in Asians. *J Cosmet Dermatol*. 2020;19(7):1636-41.
35. Patra S, Kaur M, Gupta S. Reduction of Papular Acne Scars With Needle-Guided Radiofrequency Ablation. *Dermatol Surg*. 2021;47(8):1162-3.
36. Park JY, Lee EG, Yoon MS, Lee HJ. The efficacy and safety of combined microneedle fractional radiofrequency and subablative fractional radiofrequency for acne scars in Asian skin. *J Cosmet Dermatol*. 2016;15(2):102-7.
37. Wong ITY, Richer V. Prophylaxis of Post-Inflammatory Hyperpigmentation From Energy-Based Device Treatments: A Review [Formula: see text]. *J Cutan Med Surg*. 2021;25(1):77-86.


38. West TB, Alster TS. Effect of pretreatment on the incidence of hyperpigmentation following cutaneous CO<sub>2</sub> laser resurfacing. *Dermatol Surg*. 1999;25(1):15-7.
39. Lee SJ, Ahn GR, Seo SB, Park KY, Kim BJ, Nam Kim M. Topical brimonidine-assisted laser treatment for the prevention of therapy-related erythema and hyperpigmentation. *J Cosmet Laser Ther*. 2019;21(4):225-7.
40. Hong JY, Lee HW, Park KY, Kim BJ, Kim MN. Brimonidine tartrate gel plus topical steroid for the prevention of laser therapy-related postinflammatory hyperpigmentation. *Dermatol Ther*. 2018;31(5):e12657.
41. Negishi K, Akita H, Tanaka S, Yokoyama Y, Wakamatsu S, Matsunaga K. Comparative study of treatment efficacy and the incidence of post-inflammatory hyperpigmentation with different degrees of irradiation using two different quality-switched lasers for removing solar lentigines on Asian skin. *J Eur Acad Dermatol Venereol*. 2013;27(3):307-12.
42. Chan HH, Manstein D, Yu CS, Shek S, Kono T, Wei WI. The prevalence and risk factors of post-inflammatory hyperpigmentation after fractional resurfacing in Asians. *Lasers Surg Med*. 2007;39(5):381-5.
43. Wanitphakdeedecha R, Phuardchantuk R, Manuskiatti W. The use of sunscreen starting on the first day after ablative fractional skin resurfacing. *J Eur Acad Dermatol Venereol*. 2014;28(11):1522-8.
44. Cheyasak N, Manuskiatti W, Maneeprasopchoke P, Wanitphakdeedecha R. Topical corticosteroids minimise the risk of postinflammatory hyper-pigmentation after ablative fractional CO<sub>2</sub> laser resurfacing in Asians. *Acta Derm Venereol*. 2015;95(2):201-5.
45. Vemula S, Maymone MBC, Secemsky EA, Widjajahakim R, Patzelt NM, Saade D, et al. Assessing the safety of superficial chemical peels in darker skin: A retrospective study. *J Am Acad Dermatol*. 2018;79(3):508-13 e2.
46. Agarwal N, Gupta LK, Khare AK, Kuldeep CM, Mittal A. Therapeutic response of 70% trichloroacetic acid CROSS in atrophic acne scars. *Dermatol Surg*. 2015;41(5):597-604.
47. Doddaballapur S. Microneedling with dermaroller. *J Cutan Aesthet Surg*. 2009;2(2):110-1.
48. Dogra S, Yadav S, Sarangal R. Microneedling for acne scars in Asian skin type: an effective low cost treatment modality. *J Cosmet Dermatol*. 2014;13(3):180-7.
49. Wang B, Wu Y, Luo YJ, Xu XG, Xu TH, Chen JZ, et al. Combination of intense pulsed light and fractional CO<sub>2</sub> laser treatments for patients with acne with inflammatory and scarring lesions. *Clin Exp Dermatol*. 2013;38(4):344-51.
50. Taylor MB, Koron N. Combined Treatment of Rolling Acne Scars in Ethnic Skin Using Extensive Subcision, Trichloroacetic Acid Peel, and Fractional Ablative Erbium Laser. *Dermatol Surg*. 2021;47(4):496-9.



# EMSCULPT<sup>®</sup> neo



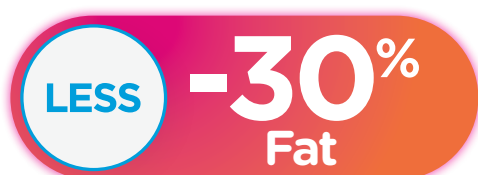Always  
Original



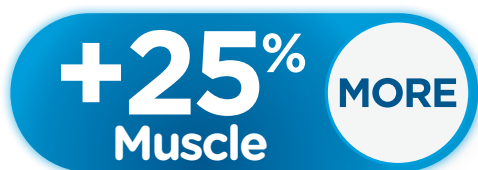30-min.  
Procedure



SALES@BTLMED.COM.AU | #EMSCULPTNEO



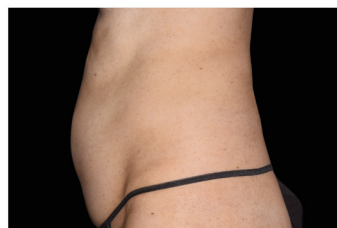on average\*



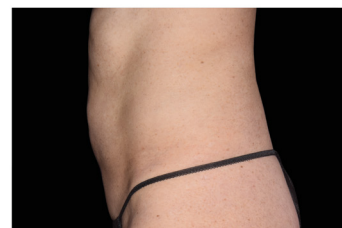on average\*

MORE for LESS

BEFORE

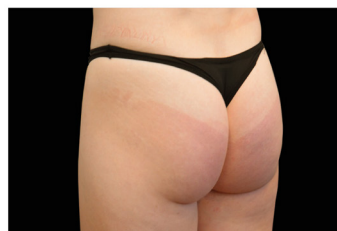

AFTER EMSCULPT<sup>®</sup>

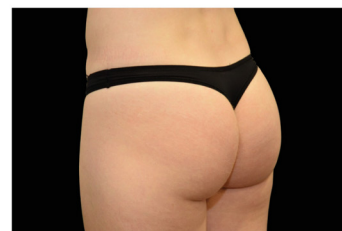

3 MONTHS AFTER THE LAST TREATMENT, COURTESY OF: BRUCE E. KATZ, M.D.

BEFORE



AFTER EMSCULPT<sup>®</sup>



IMMEDIATELY AFTER THE LAST TREATMENT, COURTESY OF: KLAUS HOFFMANN, M.D.

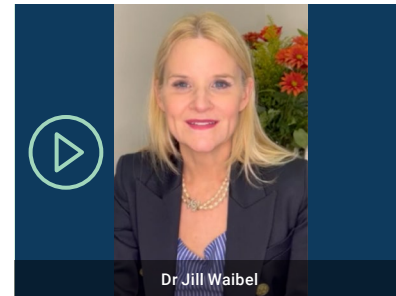We recommend following a healthy energy-controlled diet and physical activity. Please be aware that some of the information / intended uses / configurations / accessories mentioned here are not available in your country. For more information contact your local distributor. Results and patient experience may vary. As with any medical procedure, ask your doctor if the EMSCULPT NEO<sup>®</sup> procedure is right for you. In Australia EMSCULPT NEO<sup>®</sup> is intended for application of combination of bipolar radiofrequency with high-intensity electromagnetic energy for body reshaping and fat reduction by lipolysis. ©2022 BTL Group of Companies. All rights reserved. BTL and device<sup>®</sup>, EMSCULPT<sup>®</sup>, EMSCULPT NEO<sup>®</sup>, EMSELLA<sup>®</sup>, EMBODY<sup>®</sup>, EMTONE<sup>®</sup>, HIFEM<sup>®</sup>, SYNCHRODE<sup>®</sup>, EXILIS and device<sup>®</sup>, VANQUISH and device<sup>®</sup> and UNISON<sup>®</sup> are registered trademarks in Australia. Trademarks EMSCULPT, EMSCULPT NEO, EMSELLA, EMTONE, EMFEMME 360, and EMBODY are parts of EM<sup>®</sup> family of products and services. Products, the methods of manufacture or the use may be subject to one or more Australian Patent Registrations or pending applications. Any unauthorized use is expressly prohibited. \*Published clinical studies by sponsor BTL Industries JSC. Jacob C, Kent D, Ibrahim O. Efficacy and Safety of Simultaneous Application of HIFEM and Synchronized Radiofrequency for Abdominal Fat Reduction and Muscle Toning: A Multicenter Magnetic Resonance Imaging Evaluation Study. Dermatol Surg. 2021;47(7):969-973.

# Procedural options for acne scar rehabilitation

Nina Wines<sup>1</sup>, Jill Waibel<sup>2,3,4</sup>, David J. Goldberg<sup>5,6</sup>, Rebecca Quiñonez<sup>2</sup>, Shreya Andric<sup>1</sup>, Elizabeth Dawes-Higgs<sup>1</sup>, Andrea Tomizawa<sup>1,7</sup>, Ishana Dixit<sup>1</sup>

1. Northern Sydney Dermatology and Laser, Northbridge, NSW, Australia
2. Miami Dermatology and Laser Institute, Miami, FL, USA
3. University of Miami, Miami, FL, USA
4. Wright State University, Dayton, OH, USA
5. Skin Laser & Surgery Specialists, Schweiger Dermatology Group, USA
6. Icahn School of Medicine at Mt. Sinai, New York, NY, USA
7. The Skin Hospital, Darlinghurst, Sydney, NSW, Australia

Correspondence: Dr Nina Wines [info@drninawines.com](mailto:info@drninawines.com)



CLICK IMAGE TO LINK TO VIDEO

DURATION\_00:37

**OUTLINE:** Improving acne scarring is potentially transformative given the psychological, physical and social burden many patients with acne scarring experience. Considerable advances in the development of procedural modalities for acne scarring have taken place over the last decade. Physicians have a vast array of treatment options available to them. Prior to managing patients with acne scarring practitioners need to be fully acquainted with all the procedural options for the different scar types to provide their patients with the best possible care.

**KEYWORDS:** acne scars, scar, filler, subcision, laser assisted drug delivery

Wines N, Waibel J, Goldberg DJ, Quiñonez R, Andric S, Dawes-Higgs E, Tomizawa A, Dixit I. Procedural options for acne scar rehabilitation. *Opin Prog Cosmet Dermatol* 2022;2(3):41-51.

## Introduction

Acne scarring affects up to 95% of patients who have acne. Thirty percent have severe disease.<sup>1</sup> Managing acne scarring is not limited to adolescents. In our experience, a broad age range of patients present for treatment. Given acne scarring can become more apparent as the skin becomes lax with age, treatment can extend into adulthood. Managing acne scarring requires continuous planning, treatment adjustment and maintenance. Physicians need to be mindful that the psychological sequelae of acne scarring includes suicide, depression, poor self-esteem, social impairment, low academic performance and unemployment.<sup>2</sup> Delaying treatment for scarring can have detrimental consequences. It is now considered safe to perform many scar treatments in patients on isotretinoin.<sup>3</sup>

Before embarking on managing acne scarring a broad understanding of the available procedural modalities is required. Treatment recommendations are adjusted depending on scar type and severity, skin type (colour, depth and morphology), available recovery time and affordability. To holistically manage patients all aspects of post acne sequelae need to be considered and addressed including surface issues such as post

inflammatory erythema (PIE), post inflammatory hyperpigmentation (PIH), hypopigmented scars, as well as contour defects including atrophic rolling scars, boxcars, ice pick scars and hypertrophic scars. Modalities for each of these vary in effectiveness, aggressiveness, cost and downtime. There are many moving parts to scar rehabilitation and skin reconstruction and hence treatment should not be considered in isolation, but rather as a combination to achieve the best possible outcome for patients. An appreciation for which treatments to combine cannot be obtained until a thorough understanding of the advantages and disadvantages of all treatment modalities is appreciated.

Available treatment options can be broadly categorised into energy based, non-energy based, injectable and surgical. We have presented an overview of these in Table 1. Part one of this paper is designed to familiarise the reader with the various procedural options for acne scar management. Part two of the paper brings the information together to demonstrate the importance of multimodal single session treatment and assists in the planning of such treatments so as to achieve more significant outcomes for patients.

**Table 1.** Overview of procedural options for acne scarring per modality

- +++++ Very effective  
 ++++ Effective in most cases  
 +++ Good option in some cases (often requiring combination with others)  
 ++ Acceptable but inferior to other options  
 + Not really a good option unless there is no better alternative available.

Energy-based treatments					
Treatment	Downtime	Cost	Effectiveness	Scar type	Additional information
<b>Ablative laser</b>					
<b>Traditional</b> CO2 10,600 nm Er:YAG 2940 nm	Moderate 2-3 weeks	\$\$\$	+++++	Shallow Deep atrophic	High risk of side effects Largely superseded by fractional ablative
<b>Fractional</b> CO2 10,600 nm Er:YAG 2940 nm Er:YSGG 2790 nm	4-10 days depending on modality, density and depth	\$\$\$	+++++	Shallow Deep atrophic Hypertrophic scar (+/- PDL, LADD)	Need more treatment sessions for same result Higher risk of PIH High-energy, low-density settings most commonly selected <sup>4</sup> Higher energies are used for deeper scars <sup>4</sup> More effective at treating rolling and boxcars compared to NAFL
<b>Non-ablative laser</b>					
<b>Fractional non-ablative resurfacing laser</b> 1550 nm Er-glass 1565 nm fibre lasers 1927 nm thulium	Mild-moderate 4-10 days	\$\$\$	+++++	Shallow atrophic	Not as effective as fractionated ablative Less incidence of side effects. Can use safely in darker skin types
<b>Traditional non resurfacing (see Table 2)</b> 1320 nm Nd:YAG 1064 nm Nd:YAG 1450 nm Nd:YAG PDL (585-600 nm) 675 nm 755 nm Alexandrite IPL (not a laser) Picosecond 755,1064 nm Fractional Nd:YAG 1726 nm	Minimal	\$\$-\$\$\$	Variable	PIE PIH Atrophic	Traditional are outlined in Table 2. Many of these are used for PIE and PIH 1726 nm is used for long-term improvement of inflammatory acne
<b>Hybrid lasers</b>	Moderate 4-10 days	\$\$\$	++++	Atrophic	Combine ablative and non-ablative technologies to enhance results



Energy-based treatments					
Treatment	Downtime	Cost	Effectiveness	Scar type	Additional information
Radiofrequency (RF)	Minimal	\$	++++	Atrophic	A good lower cost choice Safe in darker skin types RF microneedling is more effective but associated with longer recovery time
Laser-assisted drug delivery	Mild	\$-\$	++++	Atrophic (PLLA) Hypertrophic Hypopigmented	Ablative laser is used to enhance delivery and uniformity of drug penetration
Non-energy-based procedures					
Treatment	Downtime	Cost	Effectiveness	Scar type	Addition information
Subcision	Minimal (maybe moderate if treatment is aggressive)	\$	+++++	Atrophic Rolling	There are many devices and techniques for subcision Treatment can be focal to a more generalised cosmetic unit Side effects depend on how aggressive treatment is and the device which is used Can be combined with almost every other procedure
Microneedling	Minimal	\$	+++	Atrophic	Low cost, low downtime procedure, with comparable but slightly inferior results to RF
Dermabrasion and microdermabrasion	Moderate	\$	++	Atrophic	Largely superseded by other technology
CROSS	Moderate 7-14 days PIE and PIH possible	\$	+++++	Ice pick Some boxcar	High concentrations of TCA are applied with various described precision applicators into the scar
Chemical peels	Mild-moderate	\$	++	Atrophic PIH	Energy based devices are safer and likely more effective with less side effects especially in darker skin types

Injectables					
Treatment	Downtime	Cost	Effectiveness	Scar type	Addition information
Filler	Mild-moderate	\$\$-\$\$\$	+++++	Atrophic Some boxcar	Various injection techniques exist Skill and experience influences results Filler selection is important Hyaluronic acid is likely to be the best first line option
Intralesional	Minimal	\$	+++++	Hypertrophic	Dosage and drug used depends on the scars thickness and location Lower dosages are used on the face compared to back or trunk in general
Botulinum toxin	Nil	\$\$\$	+++	Dynamic scar appearance Hypertrophic	When scar appearance is exacerbated by tissue movement botulinum toxin can significantly improve appearance Intralesional and laser assisted application is a promising alternative for hypertrophic scars
Platelet-rich plasma	Minimal	\$\$-\$\$\$	++	Atrophic	Use is probably best in combination with other procedures to enhance healing
Autologous fat	Minimal to moderate	\$\$-\$\$\$	++	Atrophic	Longevity of result is questionable
Surgical reconstruction					
Treatment	Downtime	Cost	Effectiveness	Scar type	Addition information
Punch excision	7-10 days Residual erythema until it heals	\$	++++	Ice pick Some boxcar	Useful for ice pick and deep boxcars mainly <3 mm in size
Punch elevation	7-10 days Residual erythema until it heals	\$	++++	Boxcar	Excellent for shallow and deep boxcars with sharp edges and normal bases
Elliptical excision		\$	++++	Larger irregular deeper atrophic scars	For scars >3.5 mm
Facelift	3 weeks	\$\$\$	+++++	Severe atrophic due to skin laxity	Resolves laxity and hence stretches the scar

CROSS, chemical reconstruction of skin scars; Er:YAG, erbium yttrium aluminium garnet; Er:YSGG, erbium scandium gallium garnet; fCO<sub>2</sub>, fractional CO<sub>2</sub>; HQ, hydroquinone; IPL, intense pulsed light; LADD, laser assisted drug delivery; NAFL, non-ablative fractional laser; Nd:YAG, neodymium yttrium aluminium garnet; PDL, pulse dyed laser; PIE, post inflammatory erythema; PIH, post inflammatory hyperpigmentation; PLLA, poly-L-lactic acid; RF, radiofrequency; TCA, trichloroacetic acid

## Energy-based devices

Energy-based devices have transformed the ability to prevent and manage many aspects of acne scarring and are considered first line treatments for macular post acne skin discolouration, mild and moderate atrophic scarring.<sup>4</sup> Scar prevention with early intervention of medical and laser therapy is essential. Delaying energy-based devices treatment for patients within 6 months of isotretinoin treatment effectively delays treatment for a skin disease that has major physical and mental sequelae.<sup>4</sup> Device and treatment setting selection is highly influence by the scar (type, location and morphology), characteristics of the device type, brand and power, and patient factors (downtime, finances, tolerance of discomfort). Ice pick scars are the least likely scar type to respond to energy-based devices.<sup>4</sup>

### Ablative lasers

Ablative lasers target water and remove the thin outer layer of skin (epidermis) whilst heating the underlying skin (dermis), which stimulates the growth of collagen. Whilst there is still a place for fully ablative lasers, due to high complication rate and prolonged downtime, newer fractionated devices are largely adopted as they are considered safer with less downtime and side effects, however more treatments are required to achieve the same result. These lasers treat fractions of the skin by creating microscopic columns of thermal injury with intervening normal skin which enables a more rapid onset of healing and neocollagenesis. There is a large variation between power and depth of penetration of various brands of lasers. Whilst ablative laser is more effective than non-ablative laser for acne scarring<sup>5,6</sup> the downside of ablative laser is PIH in 73.2% of patients with skin type III-IV, mostly lasting less than 3 months<sup>7</sup>, and prolonged erythema.<sup>8</sup> Erbium more closely approximates the absorption peak of water at 2940 nm and enables increased absorption of energy higher in the dermis and decreased non-specific damage to the surrounding structures. This results in less heat diffusion, a narrower rim of coagulation and less post procedure erythema.<sup>9</sup> However, there is less haemostasis during treatment, so bleeding can be an issue when using this modality and it may produce a more moderate result on remodelling compared to CO<sub>2</sub>.<sup>4</sup> Fractional erbium yttrium aluminium garnet (Er:YAG) and erbium scandium gallium garnet (Er:YSGG) have shown comparable results to fCO<sub>2</sub> after multiple treatments.<sup>10,11</sup>

### Non-ablative lasers

Non-ablative lasers generally have faster post procedural recovery time and a better side effect profile than ablative lasers, but are not as effective as ablative lasers<sup>12</sup> for acne scarring and require more treatment sessions for the same result.<sup>8</sup> Non-ablative lasers are either resurfacing lasers or non-resurfacing. Fractional resurfacing non-ablative lasers (1540, 1550, and 1927 nm) work by creating microscopic columns of thermal injury with intervening normal skin stimulating collagen growth and scar repair and generally have more efficacy than in comparison to traditional non-ablative non-resurfacing lasers. Fractional 1927 nm was recently demonstrated to be equally effective to fractional 2940 nm in a comparative split face study.<sup>13</sup> A disadvantage of these devices is that they are expensive and often have consumables associated with them.

Non-resurfacing non-ablative lasers work by targeting tissue in the dermis by selective photo thermolysis of various chromophores. These also work to stimulate collagen and dermal remodelling. Non-resurfacing lasers are best employed for macular erythema, PIE and PIH. They may have some benefit for shallow boxcars and rolling scars, but fractionated resurfacing options are likely more efficient.



**Table 2.** Utility of non-resurfacing, non-ablative lasers and energy devices in acne scarring

<b>532 nm KTP</b>	<p>Reduces vessels in the scar</p> <p>Helpful for macular erythema/PIE</p> <p>Also targets pigment</p> <p>585/595 nm may be better<sup>4</sup></p>
<b>PDL (585-600 nm)</b>	<p>Reduces vessels in scar and helps collagen remodelling response</p> <p>Helpful for macular erythema/PIE</p> <p>Better option for atrophic scars</p> <p>Also used for management of hypertrophic scars (+/- intralesional drug therapy or LADD)</p> <p>Early PDL may help reduce the incidence of atrophic acne scarring<sup>14</sup></p>
<b>675 nm</b>	<p>Helpful for hyperpigmentation and scarring</p> <p>Stimulates collagen remodelling</p> <p>Well-tolerated with no significant side effects<sup>15</sup></p>
<b>IPL/BBL</b>	<p>Results similar to PDL for macular erythema</p> <p>Allows a broader area to be treated<sup>16</sup></p> <p>An increase in collagen and elastin in the papillary dermis has been demonstrated with 550 and 570 nm filter and hence may help atrophic scars<sup>17</sup></p>
<b>Nd:YAG 1064 nm long pulsed</b>	<p>Beneficial for reducing erythema in darker skin types</p> <p>Benefits for atrophic scarring likely superseded by superior results of fractionated technologies</p>
<b>QS 1064 nm Nd:YAG (nanosecond)</b>	<p>QS Nd:YAG more commonly employed for hyperpigmented scars</p> <p>Has deeper dermal penetration</p> <p>Safe and effective for atrophic acne scarring</p> <p>Not as effective as fractional CO<sub>2</sub></p> <p>More effective for PIH<sup>4</sup></p>
<b>Picosecond laser 755 nm and 1064 nm</b>	<p>Delivered in ultrashort pulse durations</p> <p>Has a photoacoustic effect and causes less non-specific damage</p> <p>Fractional picosecond lasers are effective in acne scarring with minimal side effects<sup>18</sup></p> <p>More safely employed for darker skin types to avoid PIH and also to address pigmentary dyschromia</p> <p>755 nm demonstrates a 25-50% improvement<sup>18</sup></p> <p>Fractional Nd:YAG 1064 nm is equivalent to fractional 1550 nm and is associated with less pain but more pinpoint bleeding<sup>19</sup></p> <p>Need multiple treatments, and the costs of equipment is significant</p> <p>Picosecond lasers may have a prominent role in the management of PIH<sup>4</sup></p>
<b>1726 nm</b>	<p>Specifically targets sebocytes within the dermis</p> <p>Because of the 1726 nm induced temperature rise in the dermis acne scarring is also improved due to induction of neocollagenesis. This has now been seen subjectively in laser-treated acne patients</p> <p>Current studies are being undertaken in adult patients with acne scarring who no longer have active acne</p>

BBL, broad band light; IPL, intense pulsed light; KTP, potassium titanyl phosphate; LADD, laser-assisted drug delivery; Nd:YAG, neodymium yttrium aluminium garnet; PDL, pulse dye laser; PIE, post inflammatory erythema; PIH, post inflammatory hyperpigmentation; QS, Q-switched

## Hybrid lasers

Hybrid lasers are devices that deliver two different types of lasers at the same time during the treatment. Two examples are Sciton's Halo Hybrid™ laser delivering fractional non-ablative 1470 nm together with ablative 2940 nm, and the Alma Hybrid™ laser delivering fractional CO2 and 1570 nm together. These are thought to be more effective than single treatments alone, however larger studies are required. Results are impressive in clinical practice.

## Radiofrequency

Radiofrequency (RF) involves the use of electromagnetic energy to selectively heat the tissue at various depths causing neocollagenesis and skin contraction.<sup>8</sup> The idea is to limit the downtime by making the damage more dermally than epidermally placed. RF is associated with less expense, downtime, and pain, and lower incidence of PIH especially if the energy of the device is reduced compared to other devices.<sup>19</sup> Some devices have microneedles with tips that can be insulated or non-insulated enabling precise control of the depth at which the tissue is heated.<sup>20</sup> Due to the puncture of the stratum corneum there is some downtime for patients treated with microneedling RF and it can be painful. Of all the RF devices, fractional RF offers the best outcomes. Improvement of 25–75% can be expected after three to four sessions.<sup>8</sup> Four to five treatments are generally required. Nanofractional RF delivers energy in tiny areas and is thought to reduce the risk of PIH and has less downtime. Several treatment passes are likely to achieve better results.<sup>4</sup>

## Laser-assisted drug delivery

Laser-assisted drug delivery (LADD) enhances penetration and uniform distribution of topically applied treatments leading to enhanced delivery. Ablative lasers are used to create microscopic channels that enable drugs to travel through the epidermis. The depth and concentration of drug delivery is influenced by the laser parameters employed. LADD is mainly effective for the management of hypertrophic and keloid scars.<sup>21,22</sup> It has an emerging role in the management of other types of atrophic acne scars and hypopigmented acne scarring (Table 3).

## Non-energy-based procedures

### Subcision

Subcision is a well-tolerated and effective technique to free tethered subdermal fibrous bands that create scars.<sup>8</sup> This technique is less effective for deep boxcar and ice pick scars than rolling scars.<sup>8</sup> Several techniques and instruments are used, including 18–20G tri-bevelled hypodermic needles, 18G Nokor needles, blunt blades, cannulas and more. Tethered scars are disrupted, creating subdermal bleeding, and a subsequent blood clot is formed.<sup>27</sup> New collagen is

deposited as the clot heals, which results in a more even surface.<sup>27</sup> Subcision can be performed for single scars or more comprehensively over a wider area depending on the instrument used. Bi-level subcision refers to a two-depth technique whereby both the upper dermis and sub dermis are treated.<sup>9</sup> The best levels to perform treatment at are the deep dermis and the dermosubcutaneous junction. Care is required when subcising in deeper planes so as to not to disrupt the retaining ligaments (stable fibrous bands that attach the periosteum or deep fascia to the dermis). Disruption of these bands may result in facial sagging.<sup>28</sup> Blunt cannula subcision is associated with more favourable outcomes and less incidence of complication in comparison to Nokor needles.<sup>29</sup> Blunt blade subcision under tumescent anaesthesia has been demonstrated to be effective.<sup>30</sup>

Subcision can be combined with almost all other techniques to enhance results.<sup>9</sup> Subcision combined with hyaluronic acid filler gives better improvement than subcision alone.<sup>31</sup> Bilevel subcision combined with the injection of hybrid complexes of high and low molecular weight hyaluronan (Profilo®) using a three-step technique has recently been shown to be effective in a study of 82 patients.<sup>32</sup> Step one involves subcision with a Nokor needle using a fanning direction. Step 2 involved the injection of Profilo® at the scars atrophic dermal component with a 29G needle and third step involves the filling of the subcised space with Profilo®.<sup>32</sup> A recent study explored the use of endo-RF using a flex-RF probe in combination with subcision in nine adult patients demonstrating it is a safe and effective treatment for acne scars.<sup>33</sup>

When performing subcision in combination with energy-based devices in the same session, most experts prefer to subcise first.<sup>4</sup>

### Microneedling

Microneedling involves various devices (rollers, stampers and pens) with fine needles that create multiple punctures into the papillary and mid dermis of varying depth. Collagen production is stimulated.<sup>8</sup> Medical microneedling employs 1.5 mm–3 mm needles. Improvement has been demonstrated for superficial scars by up to 60%.<sup>34</sup> However, PIH and tram-track may occur in darker skin types.<sup>34</sup> It is considered a low cost, low downtime procedure, with comparable but slightly inferior results to RF.<sup>8</sup> There is a lack of standardisation of the depth of needles, number of passes, number of needles and post-treatment topicals applied.

### Dermabrasion and microdermabrasion

Whilst these options represent polar extremes of treatment intensity, in the authors' opinion there are other resurfacing modalities that offer fewer side effects and quicker recovery times e.g., fractional lasers, RF and microneedling. We do not tend to perform dermabrasion or microdermabrasion in our clinics.

**Table 3.** Laser-assisted drug delivery and scarring

Drug	Purpose
Triamcinolone	Hypertrophic acne scars
5-fluorouracil	Hypertrophic scars. Associated with less dermal atrophy and telangiectasia compared to triamcinolone <sup>22</sup>
Botulinum toxin	Hypertrophic scars <sup>23</sup>
PLLA	Atrophic scars <sup>24</sup>
Bimatoprost	Hypopigmented scars <sup>25</sup>
Hydroquinone	Hyperchromic scars (case report only) <sup>26</sup>

PLLA, poly-L-lactic acid

**Table 4.** Soft tissue fillers for acne scars

Soft tissue fillers	Duration of action	Composition	Comments
<b>Hylarmonic acid (HA) filler</b> <b>Belotero,</b> <b>Restylane,</b> <b>Juvederm</b>	3-12 months (perhaps longer)	Glycosaminoglycan polysaccharide (naturally occurring component of the body's connective tissue)	HA fillers differ in physical properties: degree of cross-links, HA concentration, particle size, hardness, cohesivity, and rheology (gel strength and flexibility)  Physical properties influences location of use with stronger, more cross-linked HA fillers often used for deeper filling and softer, less cross-linked fillers used for superficial filling  New hybrid complexes of high and low molecular weight hyaluronan (Profilo®) are an interesting option to consider <sup>32</sup>
<b>Calcium hydroxylapatite (CaHA)</b> <b>Radiesse</b>	1-2 years	Composed of 25-45 µm microspheres of synthetic CaHA in an aqueous gel.  Stimulates collagen production	In 10 patients with acne scars treated with 1-2 injections, at 1 year, 30% showed >75% improvement and 60% showed 50-75% improvement <sup>45</sup>
<b>Poly-L-lactic acid (PLLA)</b> <b>Sculptra</b> <b>Newfill</b>	1-2 years	Nonimmunogenic, biodegradable synthetic polymer  Induces production of collagen via increasing fibroblasts through a foreign body reaction, improving texture in time	More treatment sessions required than other fillers but produces more sustained results over 2 years <sup>8</sup>  Fractional CO2 laser assisted delivery of PLLA leads to a 33% improvement after a single treatment in 20 patients <sup>24</sup>
<b>Polymethylmethacrylate (PMMA)</b> <b>Artecoll, Artefill, Bellafill</b>	Permanent	20% PPMA microspheres, 30-50 µm, suspended in bovine collagen  Adds volume and stimulates collagen production	Cost saving method vs temporary fillers as only one treatment required  Patients with rolling scars with one treatment observed a 64% improvement <sup>46</sup>  Long term adverse effects to consider such as delayed nodules  Visible bumps may be evident if injected too superficially in the dermis <sup>32,42,43</sup>



## CROSS

Chemical reconstruction of skin scars (CROSS) involves high concentrations of trichloroacetic acid (TCA) applied with various described precision applicators into the scar. This technique is mainly used for ice pick scars but is also described for some boxcar and rolling scars. We prefer application with a fine paint brush as described by Sun and Lim<sup>35</sup> over toothpick application. Sun and Lim recommend the use of the Element Games Kolinsky Stubby Detail brush.<sup>35</sup> The trade off with TCA CROSS can be persistent PIE or PIH in darker skin types that can be managed with pre and post topical hydroquinone. Various concentrations of TCA penetrate to different depths. A 10%-30% concentration is superficial, 35%-50% is medium and >50% is deep penetrating. Optimal concentration and number of treatments is tailored to the patient, skin type and response. A 50%-70% concentration is reported as effective (>50% of patients have >50% improvement).<sup>35</sup> Sixty-five percent TCA has good to excellent result compared with 94% in the 100% TCA treated groups. A low complication rate is reported with this modality.<sup>36</sup>

## Chemical peels

Medium to deep peels are usually required for scars. Energy based devices are safer and likely more effective with less side effects especially in darker skin types. TCA 20%-35%, alpha-hydroxy acids, salicylic acids, and Jessners may help macular scars.<sup>37</sup>

## Injectables

### Fillers

Fillers are effective for atrophic scars<sup>38</sup> and work by adding volume and stimulating collagen production. Table 4 outlines soft tissue filler use for acne scars in more detail. A variety of methods such as droplet, linear threading, modified tower technique<sup>39</sup> and layered filling<sup>40</sup> have been described and are adapted according to the scar depth and type. Another study demonstrated the effectiveness of using a micro-injector to place 0.01 mL of hyaluronic acid repeatedly into the superficial dermis as being effective.<sup>41</sup>

Fillers are often combined with subcision to enhance results.<sup>38</sup> The more permanent fillers can be associated with more permanent adverse events<sup>42</sup> with delayed onset nodules reported as late as 10 years.<sup>43</sup>

There are no robust placebo-controlled trials for filler use in acne, but multiple small controlled trials indicate higher patient satisfaction with treatment and results.<sup>44</sup> Hyaluronic acid is a sensible first line choice. It is reversible, can be injected in the superficial dermis, and has a good safety profile. Whilst it is thought to last 3-12 months, recently it has been shown to last up to 10 years, particularly in areas of less movement.<sup>44</sup>

## Intralesional

Injection of triamcinolone (TAC) alone or in combination with lasers and other intralesional options such as 5-fluorouracil (5-FU) is an effective modality for the management of hypertrophic or keloidal acne scars.<sup>47</sup> We like to use insulin syringes for extra precision and comfort for patients. Red hypertrophic scars are usually first treated with vascular laser (pulsed dye laser) followed by intralesional therapy plus or minus fractionated laser. The dosage of intralesional used depends on the scar thickness and location. Lower dosages are used on the face compared to back or trunk in general. TAC and 5-FU can be used alone or in combination.

## Botulinum toxin

When scar appearance is exacerbated by tissue movement, botulinum toxin can significantly improve appearance, especially in the glabella, forehead and chin region.<sup>48</sup> Laser assisted delivery of botulinum toxin was recently demonstrated to be more effective for the management of hypertrophic scars than intralesional botulinum toxin.<sup>23</sup> This is thought to be due to the additional role of CO2 laser in improving scar outcome. It is postulated to work by minimising the growth of fibroblasts derived from the hypertrophic scar and altering the production of transforming growth factor.<sup>23</sup>

## Platelet-rich plasma

Platelet-rich plasma involves preparing and injecting the patient's own plasma to promote wound healing by delivering platelets, growth factors and cytokines to the target tissue. In the authors' opinion, the use is probably best in combination with other procedures to enhance healing. Further research and evaluation are needed to define its role in acne scar repair.

## Autologous fat transplant

Other non-filler agents include autologous fat transplant. The longevity of results of this is doubtful.<sup>9</sup>

## Surgical reconstruction

### Punch excision

Punch excision is useful for ice pick and deep boxcars mainly <3 mm in size. A punch biopsy is used to remove the scars, which need to be 4-5 mm apart. If not, then multiple sessions at least 4 weeks apart are required.<sup>8</sup> Elliptical excision is better for scars >3.5 mm.<sup>49</sup> We prefer to leave sutures in a little longer than normal for enhanced results. In practice this reduces a slight stretched appearance of the scar that may occur with early suture removal. Resurfacing laser enhances results and can be safely combined on the same day.<sup>50</sup>

## Punch elevation

Punch biopsy is used to excise the scar down to subcutaneous fat. This technique is excellent for shallow and deep boxcars with sharp edges and normal bases. Tissue is elevated to slightly above the plane of the skin and fixed with sutures or steristrips. Combination with fCO<sub>2</sub> leads to better results than fCO<sub>2</sub> alone.<sup>51</sup>

## Elliptical excision

Elliptical excision is useful for scars >3.5 mm. It may also be the best treatment for deep irregular scars in difficult locations.

## Facelift

Age related tissue laxity makes atrophic scarring more visible (especially rolling scars). A facelift can enhance the appearance of scars in this circumstance.<sup>52</sup>

## Conclusion

Advances in the array of treatment options available to physicians are considerable. These however are meaningless unless physicians can apply the correct treatments to their patients. Prior to managing patients with acne scarring practitioners need to be fully acquainted with all aspects of procedural options available to manage different types of acne scars. There are many factors to consider when performing scar rehabilitation. Single treatments are generally not performed in isolation, but rather as a combination to achieve the best and most efficient outcome for patients. This section of the paper was designed to familiarise the reader with all available procedural options prior to part 2 where we discuss the various nuances of how to bring the information together so as to design an effective single session multimodal treatment for patients.

## References

- Layton AM, Henderson CA, Cunliffe WJ. A clinical evaluation of acne scarring and its incidence. *Clin Exp Dermatol*. 1994;19:303-8.
- Tasoula E. The impact of acne vulgaris on quality of life and psychic health in young adolescents in Greece. Results of a population survey. *An Bras Dermatol*. 2012;87(6):862-9.
- Mirza F, Mirza H, Khatri A. Concomitant use of isotretinoin and lasers with implications for future guidelines: An updated systematic review. *Dermatol Ther*. 2020;33(6):e14022.
- Salameh FM, Shumaker P, Goodman G, Spring LK, Seago M, Alam M, et al. Energy Based devices for the treatment of Acne Scars: 2022 International Consensus recommendations. *Lasers Surg Med*. 2022;54(1):10-27.
- Elsaie ML, Ibrahim S, Saudi W. Fractional 10 600 nm Carbon Dioxide Laser versus Non-Ablative Fractional 1540 nm Erbium Glass Laser in Egyptian Post-acne Scar Patients. *J Laser Med Sci*. 2018;9:32-5.
- Reinholz M, Schwaiger H, Heppt MV, Poetschke J, Tietze J, Epple A, et al. Comparison of two kinds of lasers in the treatment of acne scars. *Facial Plast Surg*. 2015;31:523-31.
- Fang F, Yang H, Liu X, Ding H, Yang Y, Ge Y, et al. Treatment of acne scars with fractional carbon dioxide laser in Asians: a retrospective study to search for predicting factors associated with efficacy. *Lasers Med Sci*. 2022;37(6):2623-7.
- Boen M, Jacob C. A Review and Update of Treatment Options Using the Acne Scar Classification System. *Dermatol Surg*. 2019;45(3):411-23.
- Bhargava S, Cunha P, Lee JM, Kroumpouzos G. Acne Scarring Management: Systemic Review and Evaluation of Evidence. *Am J of Clin Dermatol*. 2018;19(4):459-77.
- Nirmal B, Pai SB, Sripathi H, Rao R, Prabhu S, Kudur MH, et al. Efficacy and safety of erbium-doped yttrium aluminium garnet fractional resurfacing laser for the treatment of facial acne scars. *Indian J Dermatol Venereol Leprol*. 2013;79:193-8.
- Kim S. Treatment of Acne scars in Asian patients using 2790nm fractional yttrium scandium gallium garnet laser. *Dermatol Surg*. 2011;37:1464-9.
- Alajlan AM, Alsuwaidan SN. Acne scars in ethnic skin treated with both non-ablative fractional 1,550 nm and ablative fractional CO<sub>2</sub> lasers: comparative retrospective analysis with recommended guidelines. *Lasers Surg Med*. 2011;43(8):787-91.
- Lu K, Cai S. Efficacy and safety comparison between 1927nm thulium laser and 2940nm Er: YAG laser in the treatment of facial atrophic acne scarring: a prospective, simultaneous split faced clinical trial. *Lasers Med Sci*. 2022;37:2025-31.
- Sarvipour N, Akbari Z, Shafie'i M, Jamali M, Ahmadvade M, Ahramiyanpour N. Lasers for the treatment of erythema, dyspigmentation, and decreased elasticity in macular acne scars: a systematic review. *Lasers Med Sci*. 2022 Aug 3. doi: 10.1007/s10103-022-03621-0.
- Cannarozzo G, Silvestri M, Tamburi F, Sicilia C, Del Duca E, Scali E, et al. A new 675nm laser device in the treatment of acne scars: An observational study. *Lasers Med Sci*. 2021. 36:227-31.
- Bellew SG, Weiss MA, Weiss RA. Comparison of intense pulse light to 595nm longpulsed laser for the treatment of hypertrophic scars and keloids. A pilot study. *J Drugs Dermatol*. 2005;4(4):448-52.
- Goldberg D. New collagen formation after dermal remodelling with an intense pulse light source. *J Cut Laser Ther*. 2000;2(2):59-61.
- Huang CH, Chang HC, Peng JH, Peng HP. Noninvasive atrophic acne scar treatment in Asians with a 755nm picosecond laser using a diffractive optioc lens- a retrospective photographic review. *Derm Surg*. 2019; 45(2):195-202.
- Chayavichitslip P, Limtong P, Triyangkulsri K, Pratumchart N. Comparison of fractional neodymium-doped yttrium aluminium garnet (Nd:YAG) 1064nm picosecond laser and fractional 1550nm erbium fiber laser in facial acne scar treatment. *Laser Med Sci*. 2020;35:695-700.
- Nitayavardhana S, Wanitphakdeedecha R, Ng JNC, Eimpunth S, Manuskiatti W. The efficacy and safety of fractional radiofrequency nanoneedle system in the treatment of atrophic acne scars in Asians. *J Cosmet Dermatol*. 2020;19(7):1636-41.
- Waibel JS, Wulkan AJ, Shumaker PR. Treatment of hypertrophic scars using laser and laser assisted corticosteroid delivery. *Laser Surg Med*. 2013;45:135-40.
- Waibel JS, Wulkan AJ, Rudnik A, Daoud A. Treatment of hypertrophic scars using laser assisted corticosteroid versus laser-assisted 5 fluorouracil delivery. *Dermatol Surg*. 2019;45(3):423-30.

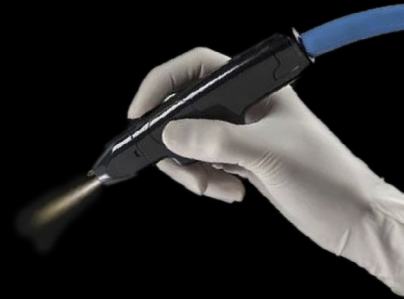23. Sabry H, Ibrahim E, Hamed M. Assessment of laser-assisted delivery vs intralesional injection of botulinum toxin A in the treatment of hypertrophic scars and keloids. *Dermatol Ther.* 2020;33:e13980.
24. Rkein A, Ozog D, Waibel JS. Treatment of atrophic scars with fractional CO2 laser facilitating delivery of topically applied poly-L-lactic acid. *Dermatol Surg.* 2014;40:624-31.
25. Waibel JS, Rudnik A, Arheart KL, Nagrani N, Gonzalez A, Gianatasio C. Re-pigmentation of hypopigmentation: fractional lasers vs laser assisted drug delivery of bimatoprost vs epidermal melanocyte harvesting system. *J Drugs Dermatol.* 2019;18:1090-6.
26. Prieto Herman Reinehr C, Kalil CLPV, de Mattos Milman L, Marchiori Bakos R. Delivery of hydroquinone assisted by fractional laser for the treatment of hyperchromic scar. *J Cosmet Dermatol.* 2020;19(12): 3451-3452.
27. Alam M, Omura N, Kaminer MS. Subcision for acne scarring: technique and outcomes in 40 patients. *Dermatol Surg.* 2005;31:310-7;discussion 7.
28. Araghi F, Dadkhahfar S, Pourani M, Gheisari M. The importance of Facial Retaining Ligaments' Preservation during subcision. *Aesthet Surg J.* 2022;42(1):2.
29. Gheisari M, Iranmanesh B, Saghi B. Blunt cannula subcision is more effective than Nokor Needle subcision for acne scars treatment. *J Cosmet Dermatol.* 2019;18:192-6.
30. Barikbin B, Akbari Z, Yousefi M, Dowlati Y. Blunt blade subcision: an evolution in the treatment of atrophic acne scars. *Dermatol Surg* 2017; 43(Suppl 1): S57-S63.
31. Ebrahim HM, Nassar A, Elkashishy K, Artima AYM, Morsi HM. A combined approach of subcision with either cross linked hyaluronic acid or threads in the treatment of atrophic acne scars. *J Cosmet Dermatol.* 2022;21(8):3334-42.
32. Mohammed G, Al-Dhubaibi MS. Triple steps acne scar revision technique: A new combination therapy modality for atrophic acne scars. *J Cosmet Dermatol.* 2022 Mar 29. doi: 10.1111/jocd.14944.
33. Nilforoushadeh MA, Heidari-Kharaji M, Fakhim T, Torkamaniha E, Nouri M, Rafiee S, et al. Endo-Radiofrequency subcision for acne scar treatment: A case series study. *J Cosmet Dermatol.* 2022;00:1-6.
34. Dogra S, Yadav S, Sarangal R. Microneedling for acne scars in Asian skin type: an effective low cost treatment modality. *J Cosmet Dermatol.* 2014;13(3):180-7.
35. Sun C, Lim D. Traichloroacetic Acid Paint for Boxcar and Polymorphic Acne Scars. *Dermatol Surg.* 2022;48(2):214-8.
36. Lee JB, Chung WG, Kwahck H, Lee KH. Focal Treatment of Acne Scars with trichloroacetic acid: chemical reconstruction of skin scar method. *Dermatol Surg.* 2002;28:1017-21.
37. Fabbrocini G, Annunziata MC, D'Arco V, De Vita V, Lodi G, Mauriello MC, et al. Acne Scars: pathogenesis, classification and treatment. *Dermato Res Pract.* 2010;2010:893090.
38. Abdel Hay R, Shalaby K, Zaher H, Hafez V, Chi CC, Dimitri S, et al. Interventions for acne scars. *Cochrane Database Syst Rev.* 2016;4:CD011946.
39. Goodman GJ, Van Deb Broek A. The modified towe vertical filler technique for the treatment of atrophic acne scarring. *Aust J Dermatol.* 2016;57(1):19-23.
40. Hussain SN, Goodman G, Rahman E. Treatment of traumatic atrophic depressed scar with Hylauronic acid fillers: a case report. *Clin Cosmet Investig Dermatol.* 2017;10:285-7.
41. Halachmi S, Amitai DB, Lapidoth M. Treatment of acne scars with hylauronic acid: an improved approach. *J Drugs Dermatol.* 2013;12:e121-3.
42. Cassuto D, Pignatti M, Pacchioni L, Boscaini G, Spaggiari A, De Santis G. Management of complications caused by permanent fillers in the face: a treatment algorithm. *Plast Reconstr Surg.* 2016; 138(2):215e-27e.
43. Salles AG, Lotierzo PH, Gemperli R, Besteiro JM, Ishida LC, Gimenez RP, et al. Complications after polymethylmethacrylate injections: report of 32 cases. *Plast Reconstr Surg.* 2008;121(5):1811-20.
44. Siperstein R, Nestor E, Meran S, Grunebaum L. A split-face, blind, randomized placebo-controlled clinical trial investigating the efficacy and safety of hyaluronic acid filler for the correction of atrophic facial scars. *J Cosmet Dermatol.* 2022;21(9):3768-78.
45. Goldberg DJ, Amin S, Hussain M. Acne Scar correction using calcium hydroxyapatite filler in a carrier gel. *J Cosmet Laser Ther.* 2004;6:223-6.
46. Karnik J, Baumann L, Bruce S, Callender V, Cohen S, Grimes P, et al. A double-blind, randomized, multicenter, controlled trial of suspended polymethylmethacrylate microspheres for the correction of atrophic facial acne scars. *J Am Acad Dermatol.* 2014;71(1):77-83.
47. Sobanko JF, Alster TS. Management of acne scarring, part I: a comparative review of laser surgical approaches. *Am J Clin Dermatol.* 2012;13:319-30.
48. Goodman GJ. Treating Scars: addressing surface, volume and movement to expedite results. Part 2: more severe grades of scarring. *Dermatol Surg.* 2012;32:1310-21.
49. Jacob CI, Dover JS, Kaminer MS. Acne Scarring: a classification system and review of treatment options. *J Am Acad Dermatol.* 2001;43:109-17.
50. Grevelink JM, White VR. Concurrent use of laser skin resurfacing and punch excision in the treatment of facial acne scarring. *Dermatol Surg.* 1998;24:527-30.
51. Faghihi G, Nouraei S, Asilian A, Keyvan S, Abtahi-Naeini B, Rakhshanpour M, et al. Efficacy of punch elevation combined with fractional carbon dioxide laser resurfacing in facial atrophic scarring: A Randomised Split-faced clinical Study. *Indian J Dermatol* 2015;60:473-8.
52. O'Daniel TG. Multimodal management of atrophic acne scarring in the aging face. *Aesth Plast Surg.* 2011;35:1143-50.



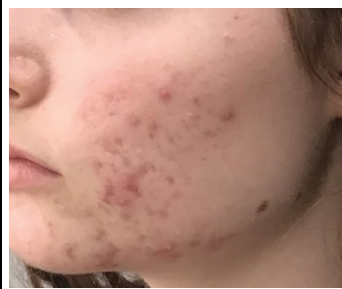MADE IN THE UK

# NeoGeneVO

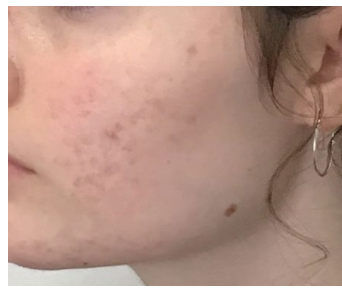## NITROGEN PLASMA SYSTEM



### INDICATED FOR ACNE SCAR REVISION

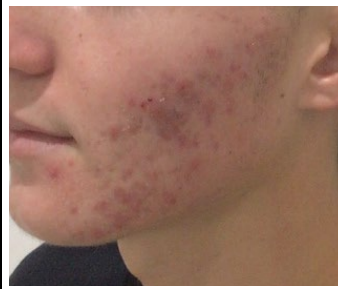

Before

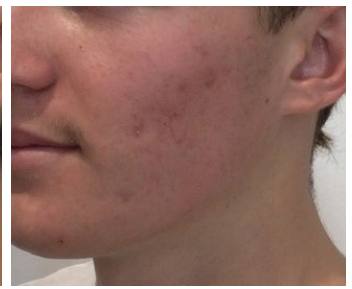

After

\*Image provided by Dr Mark Jeffery



Before



After

\*Image provided by Dr Mark Jeffery

*"The NeoGen device is an easy to use platform with less downtime for our patients instead of deep peels and other energy based devices. It treats a wide range of skin concerns and addresses the whole skin architecture and can even be used on darker skin tones. Our patients feedback has been very positive"*

**Dr. Mark Jeffery**  
OoLaLa Cosmetic and Laser Clinic



#### OTHER TREATMENT INDICATIONS

SKIN REGENERATION  
SOFT BLEPHAROPLASTY  
SKIN RESURFACING  
POST-SURGICAL SCARS  
TRAUMATIC SCARS  
ACTIVE ACNE  
FINE LINES AND WRINKLES  
SKIN TIGHTENING  
PIGMENTATION  
MELASMA  
OPEN PORES  
STRETCH MARKS  
VIRAL PAPILLOMATA  
PRE-CANCEROUS LESIONS  
AND MORE!

**MEDICAL  
DEVICE**

ARTG 311907



**AVAILABLE EXCLUSIVELY AT COSTEC**

[www.costec.com.au](http://www.costec.com.au) | [info@costec.com.au](mailto:info@costec.com.au) | 02 8331 8933

**COSTEC**  
Cosmetic Technologies

# Single session customised multimodal acne scar rehabilitation: An overview and guide to treatment planning

Nina Wines<sup>1</sup>, Jill Waibel<sup>2,3,4</sup>, Rebecca Quiñonez<sup>2</sup>, Shreya Andric<sup>1</sup>, Elizabeth Dawes-Higgs<sup>1</sup>, Andrea Tomizawa<sup>1,5</sup>, Ishana Dixit<sup>1</sup>

1. Northern Sydney Dermatology and Laser, Northbridge, Sydney
2. Miami Dermatology and Laser Institute, Miami, FL, USA
3. University of Miami, Miami, FL, USA
4. Wright State University, Dayton, OH, USA
5. The Skin Hospital, Darlinghurst, Sydney, NSW, Australia

Correspondence: Nina Wines ✉ [info@dminawines.com](mailto:info@dminawines.com)



[CLICK IMAGE TO LINK TO VIDEO](#)

DURATION\_01:24

**OUTLINE:** Acne scars remain one of the most detrimental and long-term sequelae of patients dealing with acne vulgaris. A variety of approaches are currently utilised in acne scar management including prevention, surgical correction, laser therapy, and energy-based devices. The heterogenous nature of acne scars, such as size, colour, depth, and severity, makes them a stubborn but responsive condition that requires multiple treatment modalities. Treatment burden due to perceived lack of efficacy is considerable, and costly, and the need to achieve quality results more rapidly in fewer treatment sessions is important. Combination therapies have proven to be more effective than monotherapies, and with the proper knowledge and expertise, can work safely and synergistically to expedite results. There is no current gold standard or guide for a customised single session multimodal treatment plan of acne scars; therefore, the authors present an algorithm for patient assessment and treatment planning for the management of acne scars.

Objective measurements to assess the success of a single session multimodal treatment can pose a challenge. The wide variety of scars along with their severity, and the infinite number of modalities, patient factors and treatments available make it all the more challenging. The use of a universal global grading, planning and treatment documentation system for single session multimodal treatments may assist in improving the opportunity in the future to help categorise patients by severity of scarring and number of modalities per session.

Herein, the authors discuss cases of patients with acne scars where improvement was noted by using multiple procedures in the same treatment sessions.

**KEYWORDS:** acne scars, scar, multimodal, treatment planning, subcision

Wines N, Waibel J, Quiñonez R, Andric S, Dawes-Higgs E, Tomizawa A, Dixit I. Single session customised multimodal acne scar rehabilitation: An overview and guide to treatment planning. *Opin Prog Cosmet Dermatol* 2022;2(3):53-64.

## Introduction

In today's world, time is a commodity for both patients and providers. Maximising treatment efficacy by combining procedures in one session is important, especially for those affected by acne scars. Treatment for acne and acne scars can take a prolonged period to show results, thus can place financial implications on patients.<sup>1</sup> Furthermore, acne scars can negatively influence self-esteem and self-confidence leading to a perceived decrease in employability, reduced emotional well-being, and socialisation.<sup>2,3</sup> From the

authors' clinical experience, a perceived prolongation of achieving the desired results, coupled with downtime, multiple office visits to the dermatologists, and costs of treatment, all negatively influence patients to defer treatment altogether.<sup>1</sup> There is a need for dermatologists to treat acne scars in a more effective and time efficient manner.

The advent of technology and availability of topical and oral treatment options has expanded the armamentarium of clinicians to manage acne scarring. Studies have shown that combination therapies

are more effective than monotherapies and can be performed safely and synergistically when performed by a highly trained specialist.<sup>4</sup>

Herein, the authors discuss cases of patient with acne scars where improvement was noted by using multiple procedures in the same treatment sessions.

## Acne scar pathogenesis

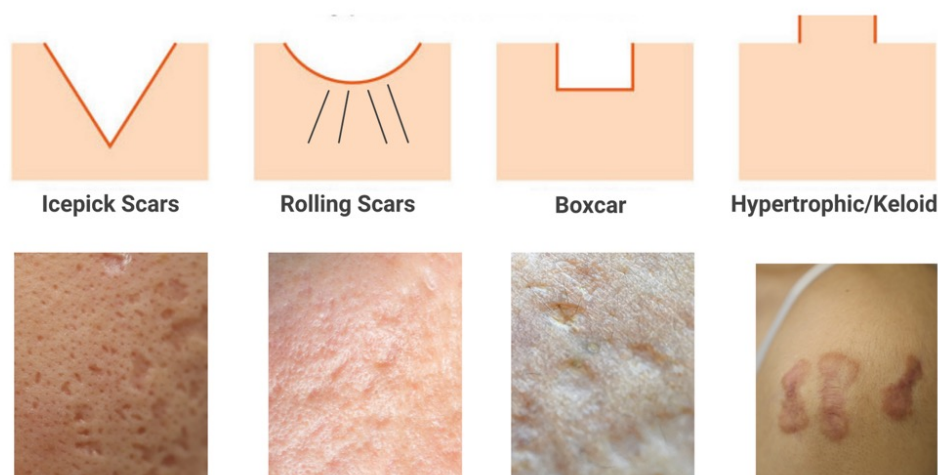
Acne scarring begins with the evolution of a non-inflamed comedone into an inflammatory lesion that ruptures through the weakened infra-infundibular section of the follicle leading to a perifollicular abscess. Outcome depends on the extent and depth of inflammation. If inflammation is severe enough it may extend directly into the subcutis.<sup>5</sup> Although the pathogenesis of acne scarring is still not fully understood, several hypotheses have been proposed. Acne scarring results from abnormal wound healing responses in cutaneous inflammation.<sup>6</sup> Wound healing is broadly divided into three stages: inflammation, granulation tissue formation, and matrix remodelling.<sup>7</sup> In patients with acne scars, the initial inflammation of the wound healing process is found to be slower, stronger, and longer in duration.<sup>8</sup> Indeed, severity of acne scars is highly correlated with the initial acne grade.<sup>9</sup> During the second stage of tissue repair, granulation tissue is formed, and new collagen is produced by fibroblasts approximately 3 to 5 days after the wound is created.<sup>10</sup> Abnormal collagen production and degradation has been found to influence the various types of acne scars. The third stage of wound healing is characterised by the formation of a lytic cascade for matrix remodelling, including extracellular matrix metalloproteinases (MMPs) and tissue inhibitors of MMP that are produced by fibroblasts and keratinocytes. Acne scars have been shown to result

from an imbalance in the ratio of these MMPs to tissue inhibitors of MMPs.<sup>11</sup> Recent studies have also confirmed a higher expression of interleukin (IL)-1 beta expression in acne vulgaris, and acne scar lesions compared to normal skin. This expression correlated to the clinical severity of acne and the degree of pathological inflammation. IL-1 beta hence could play an important role in subsequent acne scarring.<sup>12</sup>

The outcome of acne inflammation is an atrophic, hyperplastic or keloid response. Many acne scars result from a net degradation of collagen, resulting in atrophic scars in 80–90% of cases.<sup>6</sup> Types of atrophic acne scarring include ice pick, boxcar, and rolling scars (Figure 1). When the imbalance of MMPs and tissue inhibitors of MMPs results in a diminished deposition of collagen factors, atrophic scars result. Given inflammation is induced below the epidermis in the infra-infundibular region of the pilosebaceous unit, subsequent scarring often involves deeper structures. As the scar contracts, it draws in the surface layer leading to atrophy or indentation. The location, depth and extent of inflammation will determine the amount, type, and depth of scarring.<sup>5</sup>

Less commonly, an exuberant healing response leads to a net proliferation of collagen, resulting in the development of a hypertrophic scar, more common in the jaw, chest, and shoulders. Furthermore, some patients may be more prone to hypertrophic (and keloid) acne scars, and these lesions have been shown to demonstrate a lack of collagenase activity.<sup>13</sup> Superficial wounds rarely produce a hypertrophic or keloid diathesis. Keloids seem to be due to poorly resolved reticular dermal inflammation. When inflammation is confined to one or a few follicular structures a more focal type of scarring may ensue. Lost elastin from inflammation does not return and is replaced by denser collagen.<sup>14</sup>

**Figure 1.** Visual representation of acne scar types





Multiple forms of acne scars may occur in the same patient and can be influenced by other factors such as genetics, hormone dysfunction, and wound healing. Furthermore, external variables such as scratching, picking, and extracting lesions may also influence the type of scarring that occurs.

## Scar morphology

Acne scars present with a heterogeneous range of texture, colour, contour, depth, size, and severity. For these reasons, combination therapy and combining energy-based technologies with procedural modalities such as subcision, soft tissue fillers, trichloroacetic acid (TCA) chemical reconstruction of skin scars (CROSS) and punch excision in a single session provides patients with superior and faster outcomes.<sup>4</sup> Table 1 lists and describes the different types of acne scars.

Prior to managing acne scarring physicians require a full understanding of the array of procedural options that are available for acne scar rehabilitation. Within this edition we have provided an overview of various modalities to act as a guide.

The practitioner plans and designs treatment in accordance with the scar and patient factors and then oversees the treatment process over a period which varies depending on scar severity and complexity. Treatment engineering and design is adapted as the practitioner accounts for patient factors and results along the patient journey. The clinician must understand their patient's needs, emotions, budget, own limitations, and experience as well as availability and access to equipment. It is essential to remove bias to your own equipment and what it can achieve and refer to other clinics with better facilities if necessary.

**Table 1.** Overview of acne scar morphology according to their size, shape, and depth<sup>5</sup>

Type of scar	Size	Shape	Depth	Proportion
<b>Atrophic</b>				
<b>Ice pick</b>	<2 mm	V-shaped taper as it extends to dermis. Opening may be smaller than the infundibulum <sup>13,14</sup>	Deep vertical penetration into dermis to subcutaneous plane	60%
<b>Boxcar</b>	1.5-4 mm	Round to oval, sharply formed vertical edge. Opening of the infundibulum has the same width	Can be shallow (0.1-0.5 mm) or deep (>0.5-4 mm)	20%
<b>Rolling</b>	4-5 mm	Wide, shallow, sloped	Tethering of the dermis to the subcutaneous tissue	10-15%
<b>Hypertrophic</b>	Variable	Papule/nodule	Variable, 2-10 mm	10-20%
<b>Keloid</b>	Variable	Extending beyond lesion margins	Can be extensive, >10 mm	

## Single session multimodality acne scar rehabilitation – A practical guide to treatment planning

The concept of single session multimodal combination treatment was discussed by Taylor et al.<sup>15</sup> Combinations of energy-based technologies with TCA CROSS, subcision, soft tissue filler, microneedling and/or punch excision in one session expedites results compared to solo treatments and are increasingly being performed (Table 2). The authors have found that having this established method has enabled efficient preparation for treatments and has ensured the booking of patients appropriately. Planning ahead of time assures clinicians have ample time to follow-up with patients and enhance the outcome and overall experience for patients. The number of total sessions is determined at every follow-up visit, however, having a clear expectation should be set in the initial consult.

## Case studies


Patient communication is paramount to successful management and planning of acne scar treatment. The authors present four cases to emphasise the impact of patients' expectations, financial implications, and timeframes for treatment on planning. Other factors that impact design include scar type, severity, skin type and the presence or absence of active inflammatory acne.

**Table 2.** List of studies using combination treatments leading to more effective results than single treatments alone

<b>fCO2 combination</b>	<p>fCO2 + IPL is effective in Chinese patients: 4-6 sessions<sup>16</sup></p> <p>fCO2 + PRP intradermal injections<sup>17</sup></p> <p>fCO2 + allogenic stem cells<sup>18</sup></p> <p>fCO2 + RF intensifies thermal effect and provides better results in less time with fewer treatment sessions<sup>19-20</sup></p> <p>Spot fCO2 plus global non-ablative fractional laser<sup>21</sup></p>
<b>Microneedling combination</b>	<p>Microneedling + PRP or glycolic peels improvement in acne scarring increased to 62%<sup>22</sup></p> <p>Microneedling + PMMA<sup>23</sup></p>
<b>Subcision</b>	<p>Subcision prior to fCO2 yields better results<sup>24</sup></p> <p>Microneedling RF combined with prior subcision leads to better results than microneedling RF alone<sup>25</sup></p> <p>Microneedling followed by PMMA in 14 patients lead to 96% improvement<sup>26</sup></p> <p>Microneedling + fillers + 1320 Nd:YAG combination led to superior results<sup>27,28</sup></p> <p>Microneedling + 20% TCA peel + fractional ablative erbium under tumescent anaesthetic<sup>15</sup></p> <p>Microneedling + Cross-Linked HA or PLLA threads<sup>29</sup></p> <p>Microneedling + Endolift (200 nm fibres)<sup>30</sup></p> <p>Microneedling + PRP<sup>31</sup></p>
<b>Chemicals</b>	<p>Acids + fractional radiofrequency<sup>32</sup></p>

fCO2, fractional CO2; HA, hyaluronic acid; IPL, intense pulsed light; Nd:YAG, neodymium yttrium aluminium garnet; PLLA, poly-L-lactic acid; PMMA, polymethylmethacrylate; PRP, platelet-rich plasma; RF, radiofrequency; TCA, trichloroacetic acid

**Case 1.**

Patient factors	Skin and scar factors	Treatment plan/execution
Caucasian 60 yo Busy executive Limited time Wanted results quickly Cost not a concern No previous treatment	FST II Subcutaneous atrophic scarring Atrophic dermal scarring Boxcars and ice pick scars	<b>One session: Layered HA filler</b> <b>Step 1:</b> Deep subcutaneous injection first with cannula Slow bolus injection of high cross-linked HA 20 mg/mL (2 mL) <b>Step 2:</b> Superficial subcision with blunt cannula technique followed by HA 17.5 mg/mL subdermally (2 mL) <b>Step 3:</b> Superficial droplet injection HA to rolling superficial scars <b>Step 4:</b> TCA 70% brush technique to ice pick scars <b>Reviewed</b> 3 months later for second session with longer-acting filler. No treatment required as results sustained. <b>Maintenance</b> Review annually and gradually switch to a longer-acting filler.
 <p>a. before b. after</p>		

**Case 2.**

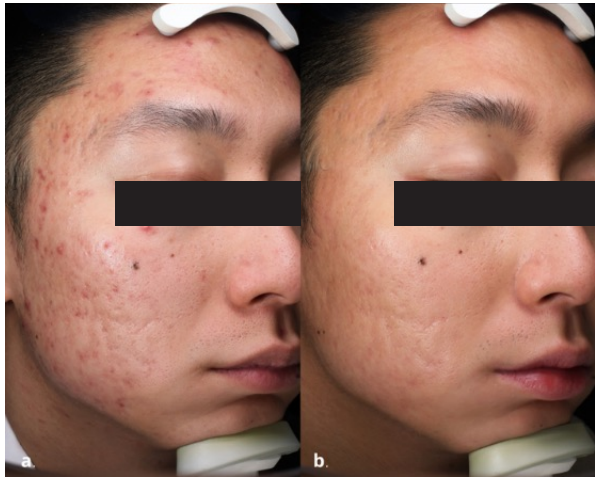
Patient factors	Skin and scar factors	Treatment plan/execution
Asian 26 yo Health care worker Limited time Wanted minimal downtime and gradual results over a 2-year period Finances a concern No previous treatments	FST III Ice pick and box scarring largely Lesions close together	<b>Three sessions</b> <b>Session 1: Introductory test patch</b> Designed to ease the patient into treatment to demonstrate result and downtime of various techniques. A small number of punch elevations, punch excision performed and trial of TCA 50% and 70% brush performed. <b>Session 2: 4 weeks later</b> Patient indicated she liked the results of TCA 70% and preferred punch elevation to punch excision. However, on close inspection the rim of punch elevation could be seen. Whilst this could be resurfaced, she elected not to have this done due to potential downtime. She progressed to a session of TCA 70% alone followed by post treatment HQ (Tri-Luma®) starting day 7 post treatment. RF also performed on the same day. <b>Session 3: 6 weeks later</b> 30% improved. Repeat of the above. Patient very pleased with results. Due to her personal time constraints and desire for minimal downtime and slow results, 3 further sessions planned over the 12-month interval. Hoping to progress her to fractionated resurfacing for blending. <b>Maintenance</b> Once a satisfactory end point is achieved annual review to monitor progress.
 <p>a. Visia Standardised before photo b. Macro view c. Session 1 – introductory test patch</p>		



**Case 3.**

Patient factors	Skin and scar factors	Treatment plan/execution
Indian descent 36 yo Recent immigrant to Australia Works in hospitality Commute to medical office a concern, time off work and financial implications a concern Profound effects on self esteem	FST IV Atrophic, boxcar, rolling, linear, and some with combined morphology	<b>Two sessions</b> <b>Session 1</b> Goal to achieve as much impact in one session as possible. Was able to source a compassionate supply of filler. <b>Step 1:</b> Subcision – relatively aggressive, followed by layered HA filler of different cross linking followed by superficial droplet filler <b>Step 2:</b> Surgical excision larger scars > 3.5 mm. Punch excision some 2-3 mm ice pick and boxcars <b>Step 3:</b> TCA CROSS using brush technique <b>Step 4:</b> fCO2 (low density high fluence) and RF <b>Step 5:</b> Post treatment HQ after suture removal Follow-up with emailed photography monthly. <b>Session 2: 3 months later</b> <b>Step 1:</b> Repeat subcision and layered HA filler followed by droplet filler <b>Step 2:</b> Combination RF and fCO2 <b>Step 3:</b> Post treatment HQ (Tri-Luma®) <b>Maintenance</b> Single annual treatment planned thereafter.
 <p>a. Visia Standardised before photo b. Macro view</p>		

**Case 4.**

Patient factors	Skin and scar factors	Treatment plan/execution
Asian 26 yo University student, just graduating and taking on a major first job Expects results in 3 months, prior to starting job No downtime available once new career starts	FST III Atrophic and ice pick scars Moderate inflammatory acne	Discussed with patient realistic expectations given time frame and active acne lesions. Pre-treatment with oral isotretinoin 20 mg for 8 weeks prior to commencing treatment. Patient to remain on isotretinoin throughout the course of acne scarring treatment. <b>Session 1: 8 weeks after low dose isotretinoin</b> <b>Step 1:</b> Subcision followed by layered HA filler (20 mg/mL and 17.5 mg/mL – one mL of each due to financial factors) <b>Step 2:</b> RF to reduce downtime in combination with light low-density CO2 given intercurrent isotretinoin, downtime available and risk of PIH <b>Session 2: 3 months later due to work commitments</b> Same as above <b>Plan for further sessions</b> – time frame uncertain due to intensity of his new job and commitments. Aiming for 2 further 6 monthly sessions until has reached satisfied endpoint. <b>Maintenance</b> Annual review to determine if top up treatments required.
 <p>a. Visia Standardised before photo b. After isotretinoin for 8 weeks</p>		

CROSS, chemical removal of scar tissue; fCO2, fractional CO2; HA, hyaluronic acid; HQ, hydroquinone; PIH, post-inflammatory hyperpigmentation; RF, radiofrequency; TCA, trichloroacetic acid

## Designing the single session multimodal treatment plan

Accurately assessing a patient's skin type and type of acne scar is an important component for determining a treatment plan. In the authors' collective experience, patients appreciate a clinician who empathises with the impact acne scarring has made on their social and professional life. Clinicians should remain empathetic and understanding, while also establishing reasonable expectations of treatment outcomes.

### Step 1. Classify and grade acne severity

The most adopted system is the Qualitative Scarring Grading System first described by Goodman and Baron in 2006.<sup>33</sup> This is a simple index of severity that can be compared over time between clinicians and treatment sessions. Acne scars are subdivided into grades 1-4 based on scar severity. The system further categorises the scar according to its distribution with focal involvement of a single cosmetic unit as "A" and two or three areas of distinct disease involvement as "B" (Table 3). Grading enables a quantitative overall impression of the individual's acne scarring severity.

When it comes to treatment planning physicians need to be cognisant of the topographical variation in surface contour of scarring within each individual. Scar type varies from location to location on the face. Atrophy topography can also vary from superficial, to subdermal to subcutaneous within the same patient. Technique and modality vary depending on the scar type and atrophic scar depth. By way of example, subcision with or without a less cross-linked hyaluronic acid filler may be performed for superficial subdermal atrophic scars and then a higher cross-linked hyaluronic acid filler may be employed for the deeper subcutaneous scarring. Other modalities will be required depending on scar type within that patient. For example, TCA CROSS with brush may be used for ice pick scars and intralesional corticosteroids employed for hypertrophic scars. The physician may also need punch devices should surgical procedures be performed for the individual.

Within this edition Goodman discusses the classification and management of less severe surface predominant acne scarring versus severe atrophic acne scarring.

### Step 2: Assess skin type

Skin type influences choice of treatment. Darker skin types can be managed with most modalities, and when necessary, precautions are taken. An array of cosmeceutical agents may be used for preprocedural and post-procedural management. One study reports that starting patients on hydroquinone once daily for 6 weeks prior to treatment can decrease the potential for post-inflammatory hyperpigmentation (PIH).<sup>34</sup> Lowering the densities, fluence and number of passes when using energy devices and avoiding aggressive techniques enables effective management. Longer pulse durations, epidermal cooling and spacing treatments further apart are also helpful. A short course of topical corticosteroids post treatment may also be helpful. Discussion about proper photoprotection cannot be underestimated and patients should be counselled appropriately.

### Step 3: Surface colour – red, brown, or white

Examine the skin for underlying skin dyschromia or other conditions, such as rosacea. Determine if there is any post-inflammatory erythema, post-inflammatory hyperpigmentation or hypopigmentation that the patient wishes to address. Within this edition, Goodman discusses options for the management of surface colour in patients with less severe surface predominant acne scarring.

In addition to options mentioned by Goodman it is worthy to note the beneficial effect of topical pharmaceuticals for post-acne scar hyperpigmentation. Retinoids used in combination with hydroquinone and corticosteroids are effective, but can cause irritation.<sup>35</sup> Hydroquinone is used in combination with retinoids and corticosteroids. Risk of irritation, steroid-induced atrophy and ochronosis can occur;<sup>35</sup> the authors' preferred agent is Tri-Luma® (fluocinonide acetone, hydroquinone, plus tretinoin). Azelaic acid

**Table 3.** Qualitative Scarring Grading System by Goodman and Baron<sup>33</sup>

Grade	Level	Clinical features
1	Macular	Erythematous, hyper- or hypopigmented flat marks (colour problem)
2	Mild	Atrophy or hypertrophy may not be obvious at social distances of $\geq 50$ cm, covered by makeup or the shadow of shaved beard hair (men) or normal body hair
3	Moderate	Atrophic or hypertrophic scarring is obvious at social distances of $\geq 50$ cm, not covered by makeup or the shadow of shaved beard hair (men) or normal body hair; atrophic scars can be flattened by manual stretching of the skin
4	Severe	Atrophic or hypertrophic scarring is evident at social distances of $\geq 50$ cm; not covered by makeup or atrophic scars and not flattened by manual stretching of the skin

demonstrated improvement at 4 weeks with ongoing results at 16 weeks of application. Minor irritation can occur but unlike other options it is safe in pregnancy, or for patients who cannot tolerate retinoids.<sup>36</sup> Oral isotretinoin is effective at preventing PIH when used for concomitant severe acne scarring.<sup>38</sup> Chemical peels may be helpful such as Jessners and salicylic acid 30%.<sup>49</sup> Oral tranexamic acid may be useful to treat or prevent PIH.<sup>39</sup> Medical treatment may be used in combination with other modalities to enhance results.

#### Step 4. Consider the patient's needs and complete the treatment plan

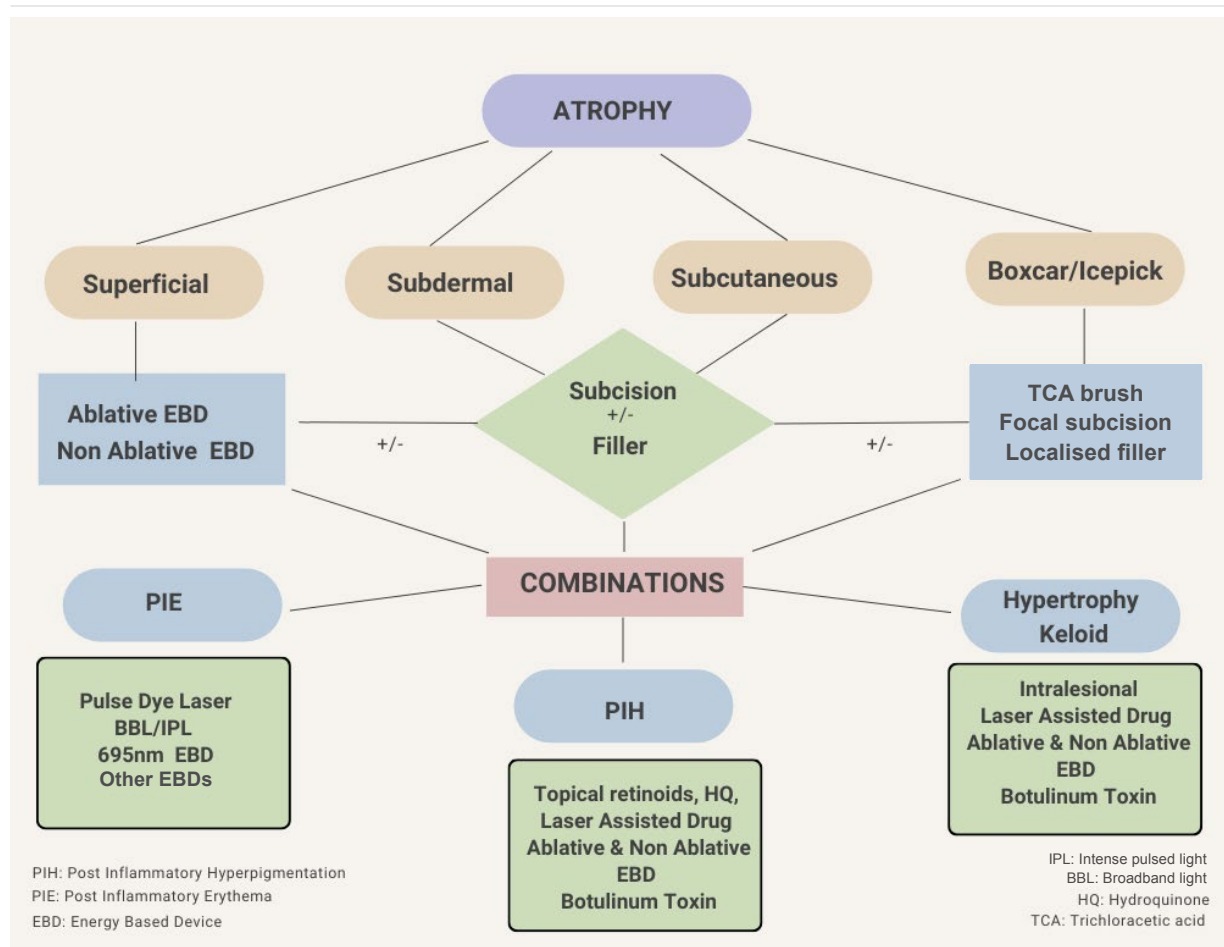
After completing the first steps, a flow chart (Figure 2) can help to determine the range of treatments to institute.

Choices are then altered according to downtime, acceptance of risk, travel cost or distance, ability to tolerate discomfort level and impacts of cost of treatment. For example, patients on a limited budget might consider treatments such as microneedling or

radiofrequency. On the other hand, patients without monetary concerns can opt for fractionated lasers in combination with subcision, fillers, and CROSS combinations all within one session. The primary goal of the physician is to optimise a plan for each patient that works with their primary concerns and lifestyle factors. Finally, clinicians need to communicate to patients a realistic timeframe for results. In moderate to severe cases several sessions over an 18-month to 2-year period may be required. Patients need to appreciate that consistent maintenance treatments on an annual basis can help sustain and build on outcome given acne scarring may alter in appearance as the skin laxity develops with age.

Due to the lack of appropriate medical software systems specific to acne scarring, the authors have developed a manual treatment planning sheet that has worked effectively in their clinic (Appendix 1). This has assisted the administrative team to book treatment and the nursing team to prepare for treatments.

Figure 2. Acne scarring treatment flow chart





Limitations of single session multimodal therapy

With all processes there are advantages and disadvantages. The authors have explored the pros and cons of single session multimodal therapy in Table 4.

Table 4. Advantages and disadvantages of single session multimodal acne scar rehabilitation

Advantages	Disadvantages
Superior outcome	High learning curve
Higher patient satisfaction	Vast array of costly equipment required
Less cost overall for patient, but higher cost per treatment	Difficulty in measuring outcome
Less global downtime for patients	Multiple treatments still required, but less overall treatment sessions
	Procedural time for physicians (30-60 min)

The value and complexity of photographing acne scar patients

Photography before each treatment is essential to document patients' progress. However, photographically documenting acne scarring is challenging. Facial photography devices do not adequately document the topographic features and contour defects of atrophic scarring (Figures 3 and 4). Angled tangential light from above the patient highlights atrophy and textural change. Most standardised photo systems use directed illumination which causes scars to disappear. Colour imaging alone does not allow for volumetric assessment of the scar. Three-dimensional photographic imaging software can calculate volume but cannot effectively demonstrate erythema and dyschromia.<sup>40</sup> The Canfield 3D Primos can capture high-resolution 3D images to demonstrate fine surface details and can demonstrate objective measures of scar depth and volume.

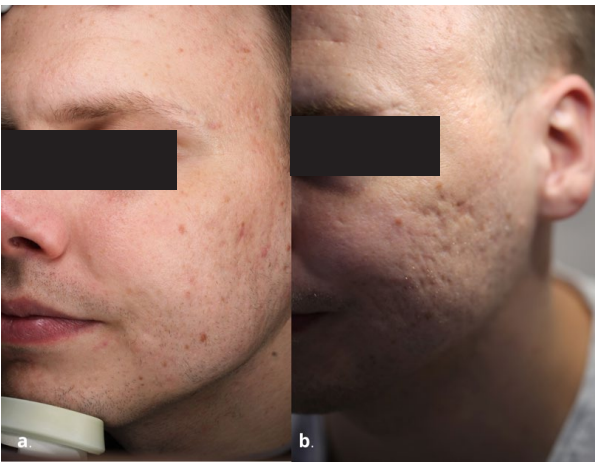


Figure 3. The influence of lighting on photographic documentation of acne scarring. a. Visia standardised skin imaging. b. Digital SLR camera with light angled tangentially above the head

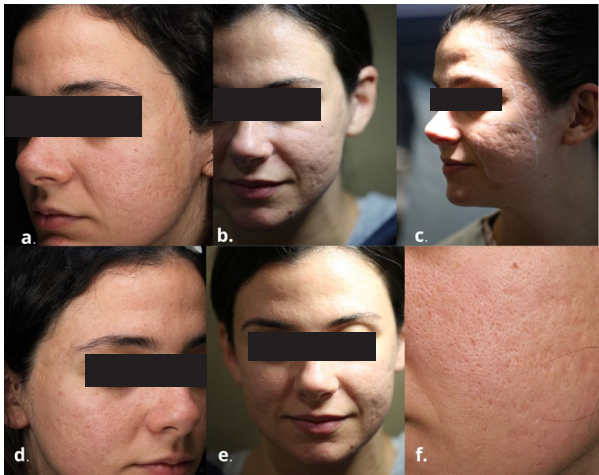


Figure 4. Further demonstration of the influence of lighting on photographic documentation on acne scarring. a,d,f Canfield Visia imaging; b,c,e DSLR camera with light at different angles.

Treatment execution

With an effective plan, clinical staff can adequately prepare each patient's treatment, so everything is readily available. Planning and prediction of the number of sessions ensures enough capacity in the working plan to perform treatments at desired intervals for patients. The authors have developed a treatment documentation sheet that has worked effectively in their clinic. In time, the use of an agreed upon universal global grading, planning and treatment documentation system for single session multimodal treatments may assist in improving the opportunity in the future to help categorise patients into severity and number of modalities per session. A quantitative and likely computerised 3D point scoring accounting for severity, volume and dyschromia would be ideal to determine effectiveness of single session multimodality treatment.

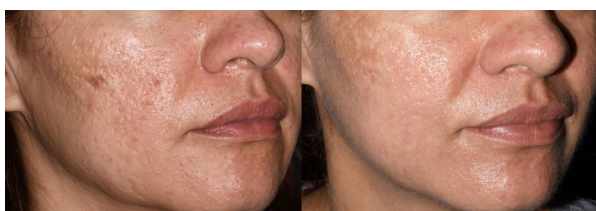

Figure 5. Before and after photos courtesy Dr Jill Waibel

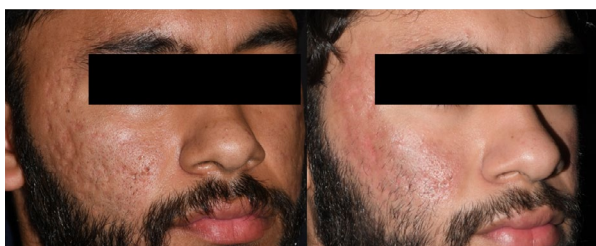

Figure 6. Before and after photos courtesy Dr Jill Waibel

## Conclusion

Single session customised multimodal acne scar rehabilitation offers patients more rapid results and outcomes with less total physical and personal downtime. Results that can be achieved are indicated in Figure 5 and 6. While it may seem like a high initial cost, fewer treatment visits may decrease time off work, commuting expenses, and overall financial cost of treatments over time. The infinite possible combinations of acne scar treatments make measuring the success of a single session multimodal treatment challenging. It is the authors' hope that this manuscript allows physicians to feel more comfortable in establishing a multimodal treatment plan in one visit, patient permitting.

## References

1. Tan J, Chavda R, Leclerc M, Brigitte D. Projective Personification Approach to the Experience of People with Acne and Acne Scarring—Expressing the Unspoken. *JAMA Dermatol* 2022; 158(9):E1–E7.
2. Halvorsen JA, Stern RS, Dalgard F, Thoresen M, Bjertness E, Lien L. Suicidal ideation, mental health problems, and social impairment are increased in adolescents with acne: a population-based study. *J Invest Dermatol*. 2011;131:363–70.
3. Dreno BL, Bettoli V, Torres Lozada V, Kang S. Global Alliance to Improve Outcomes in Acne. Evaluation of the prevalence, risk factors, clinical characteristics, and burden of acne scars amongst active acne patients who consulted a dermatologist in Brazil, France and the USA. Present 23rd EADV Congr Amst Netherland. 2014; (P024).
4. Zaleski-Larsen LA, Fabi SG, McGraw T, Taylor M. Acne Scar Treatment: a multimodal approach tailored to scar type. *Dermatol Surg*. 2016; 139–49.
5. Goodman GJ. Postacne Scarring: A Review of its Pathophysiology and Treatment. *Dermatol Surg* 2000;26:857–71.
6. Connolly D, Vu HL et al. Acne Scarring – Pathogenesis, Evaluation and Treatment Options. *J Clin Aesthet Dermatol*. 2017; 10(9): 12–23.
7. Fabbrocini G, Annunziata MC, D'Arco V, De Vita V, Lodi G, Mauriello MC, et al. Acne scars: pathogenesis, classification and treatment. *Dermatol Res Pract*. 2010;2010:893080.
8. Holland DB, Jeremy AHT, Roberts SG, Seukeran DC, Layton AM, Cunliffe WJ. Inflammation in acne scarring: a comparison of the responses in lesions from patients prone and not prone to scar. *Br J Dermatol*. 2004;150(1):72–81.
9. Layton AM, Henderson CA, Cunliffe WJ. A clinical evaluation of acne scarring and its incidence. *Clin Exp Dermatol*. 1994;19(4):303–8.
10. Baum CL, Arpey CJ. Normal cutaneous wound healing: clinical correlation with cellular and molecular events. *Dermatol Surg*. 2005;31(6):674–686.
11. Chivot M, Pawin H, Beylot C, Chosidow O, Dreno B, Faure M, et al. Cicatrices d'acné: épidémiologie, physiopathologie, clinique, traitement [Acne scars: epidemiology, physiopathology, clinical features and treatment]. *Ann Dermatol Venereol*. 2006;133(10):813–24.
12. ElAttar Y, Mourad B, Alngomy HA, Shams El Deen A, Ismail M. Study of interleukin-1 beta expression in acne vulgaris and acne scars. *J Cosmet Dermatol*. 2022 Feb 16. doi: 10.1111/jocd.14852. Epub ahead of print.
13. Alster TS, Tanzi EL. Hypertrophic scars and keloids: etiology and management. *Am J Clin Dermatol*. 2003;4(4):235–43.
14. Goodman GJ. Commentary on a Neglected Acne Scar Type: Papular Acne Scars and Their Correlations with Keloid Scars. *Dermatol Surg*. 2021;47(10):1352–3.
15. Taylor MB, Koron N. Combined Treatment of Rolling Acne Scars in Ethnic Skin Using Extensive Subcision, Trichloroacetic Acid Peel, and Fractional Ablative Erbium Laser. *Dermatol Surg*. 2021;47(4):496.
16. Wang B, Wu Y, Luo YJ, Xu XG, Xu TH, Chen JZ, et al. Combination of intense pulsed light and fractional CO<sub>2</sub> laser treatments for patients with acne with inflammatory and scarring lesions. *Clin Exp Dermatol*. 2013;38(4):344–51.
17. Galal O, Tawfik AA, Abdalla N, Soliman M. Fractional CO<sub>2</sub> laser versus combined platelet rich plasma and fractional CO<sub>2</sub> laser in the treatment of acne scars. Image analysis system evaluation. *J Cosmet Dermatol*. 2019; 18. 1665–71.
18. Zhou BR, Zhang T, Bin Jameel AA, Xu Y, Xu Y, Guo SL, et al. The efficacy of conditioned media of adipose-derived stem cells combined with ablative carbon dioxide fractional resurfacing for atrophic acne scars and skin rejuvenation. *J Cosmet Laser Ther*. 2016. 18: 138–48.
19. Cameli N, Mariano M, Serio M, Ardigo M. Preliminary comparison of fractional laser with fractional laser plus radiofrequency for the treatment of acne scars and photoaging. *Dermatol Surg* 2014;40:553–61.
20. Tenna S, Cogliandro A, Piombino L, Filoni A, Persichetti P. Combined use of fractional CO<sub>2</sub> laser and radiofrequency waves to treat acne scars: a pilot study on 15 patients. *J Cosmet Laser Ther*. 2012;14(4):166–71.
21. Simmons BJ, Griffith RD, Falto-Aizpuruna LA, Nouri K. Use of radiofrequency in cosmetic dermatology: focus on nonablative treatment of acne scars. *Clin Cosmet Investig Dermatol*. 2014;7:335–9.
22. Asif M, Kanodia S, Singh K. Combined autologous platelet-rich plasma with microneedling versus microneedling with distilled water in the treatment of atrophic acne scars: a concurrent split face study. *J Cosmet Dermatol* 2016; 15: 434–43.

23. Biesman BS, Cohen JL, DiBernardo BE, Emer JJ, Geronemus RG, Gold MH, et al. Treatment of Atrophic Acne scars with Microneedling followed by polymethylmethacrylate Collagen gel Dermal filler. *Dermatol Surg* 2019; 45: 1570-9.
24. Faghini G, Poostiyan N, Asilian A, Abtahi-Naeini B, Shahbazi M, Iraj F, et al. Efficacy of fractionated microneedling radiofrequency with and without subcision for the treatment of atrophic facial scars: a randomised split faced clinical study. *J Cosmet Dermatol* 2017; 16:223-9.
26. Epstein RE, Spencer JM. Corection of atrophic scars with ArteFill: an open- label pilot study. *J Drugs Dermatol*. 2010;9:1062-4.
27. Fulchiero GJ, Parham-Vetter PC, Obagi S. Subcision and 1320nm Nd:Yag nonablative laser resurfacing for the treatment of acne scars: a simultaneous split-face single patient trial. *Dermatol Surg* 2004; 30: 1356-9.
28. Alam M, Omura N, Kaminer MS. Subcision for acne scarring: technique and outcomes in 40 patients. *Dermatol Surg* 2005;31:310-7.
29. Ebrahim HM, Nassar A, Elkashishy K, Artima AYM, Morsi HM. A combined approach of subcision with either cross-linked hylauronic acid or threads in the treatment of Atrophic Acne Scars. *J Coll Physicians Surg Pak*. 2021; 31:55-9.
30. Nilfroushzadeh MA, Fakhim T, Heidari-Kharaji M, Hanifnia AR, Hejazi S, Torkamaniha E. Efficacy evaluation of Endolift based subcision on acne scar acne scar treatment. *J Cosmet Dermatol* 2021. 20: 2579-2582.
31. Deshmukh NS, Belgaumkar VA. Platelet-Rich Plasma augments Subcision in Atrophic Acne Scars. A Split Face comparative study. *Dermatol Surg* 2019; 45: 90-8.
32. Chilicka-Hebel K, Pagacz K. The use of combination therapy with 20% glycolic acid and fractional mesotherapy to reduce acne scars: a case report. *Med Sci Pulse*. 2019;13:49-51.
33. Goodman GJ, Baron JA. Postacne scarring- a quantitative global grading system. *Dermatol Surg*. 2006;32(12):1458-66.
34. Quiñonez RL, Agbai ON, Burgess CM, Taylor SC. An update on cosmetic procedures in people of color. Part 1: Scientific background, assessment, preprocedure preparation. *J Am Acad Dermatol*. 2022 Apr;86(4):715-25.
35. Callender VD, Baldwin H, Cook-Bolden FE, Alexis AF, Stein Gold L, Guenin E. Effects of Topical Retinoids on Acne and Post-inflammatory Hyperpigmentation in Patients with Skin of Color: A Clinical Review and Implications for Practice. *Am J Clin Dermatol*. 2022;23(1):69-81.
36. Kircik LH. Efficacy and safety of azelaic acid (AzA) gel 15% in the treatment of post-inflammatory hyperpigmentation and acne: a 16-week, baseline-controlled study. *J Drugs Dermatol*. 2011;10(6):586-90.
37. How KN, Lim PY, Wan Ahmad Kammal WSL, Shamsudin N. Efficacy and safety of Jessner's solution peel in comparison with salicylic acid 30% peel in the management of patients with acne vulgaris and postacne hyperpigmentation with skin of color: a randomized, double-blinded, split-face, controlled trial. *Int J Dermatol*. 2020;59(7):804-12.
38. Winhoven SM, Ahmed I, Owen CM, Lear JT. Postinflammatory hyperpigmentation in an Asian patient: a dramatic response to oral isotretinoin (13-cis-retinoic acid). *Br J Dermatol*. 2005;152(2):368-9.
39. Lindgren A, Austin AH, Welsh KM. The use of Tranexamic Acid to Prevent and Treat Post-Inflammatory Hyperpigmentation. *J Drug Dermatol* 2021; 20(3):344-5.
40. Clark A, Saric S, Sivamani R. Acne Scars: How do we grade them *Am J of Clin Dermatol*. 2018; 19(2): 139-44.



## Appendix 1 – Treatment plan

## Single Session Acne Scar Rehabilitation Treatment Plan

Patients Name: \_\_\_\_\_ DOB: \_\_\_\_\_

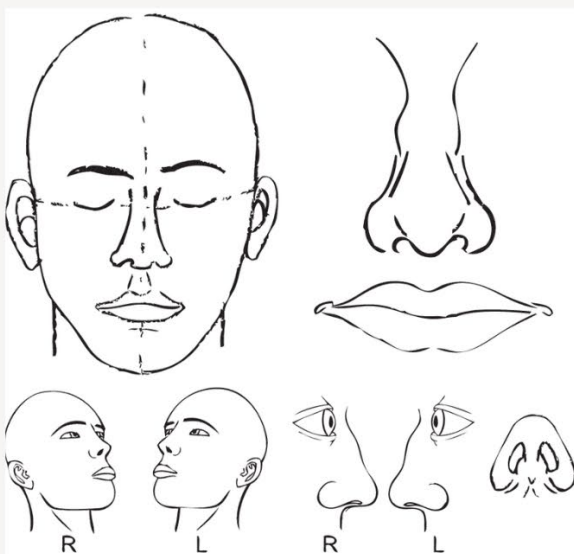
Practitioner/s: \_\_\_\_\_ Date: \_\_\_\_\_

## G &amp; B Scar Grade

<input type="radio"/> 1a	<input type="radio"/> 1b
<input type="radio"/> 2a	<input type="radio"/> 2b
<input type="radio"/> 3a	<input type="radio"/> 3b
<input type="radio"/> 4a	<input type="radio"/> 4b

## SCAR TYPES

☐ ICEPICK    ☒ ATROPHIC DERMAL    ☐ HYPERTROPHIC  
☐ BOX    ☒ ATROPHIC SUB    ☐ KELOID

SURFACE COLOUR ☐ Red ☐ Brown ☐ White

**PATIENT FACTORS**

	Mild	Moderate	Severe
Psychological impact:	<input type="radio"/>	<input type="radio"/>	<input type="radio"/>
	Minimal	Moderate	No Concern
Downtime Available:	<input type="radio"/>	<input type="radio"/>	<input type="radio"/>

## ADDITIONAL PT INFO/NOTES

- ☐ Pre treatment photos taken  
☐ Patient Information given  
☐ Consent information given  
☐ Quote received

## APPOINTMENTS/INSTRUCTIONS

TLA- topical local anaesthetic

## SKIN TYPE/CONCERNS/PASTRX

## TREATMENT PLAN

(Circle which treatment)

## SESSION 1

CO2	Subcision	<b>Appt Length</b>
Erbium	Microneedling	
1550nm 1927nm	TCA Cross %	<b>TLA Y/N Time</b>
595nm 1064nm	Filler	
BBL	Punch	<b>Quote</b>
RF	Elliptical	
Pico	TAC/ 5 FU	<b>Rx Interval</b>
QS	Botulinum	

Filler Type/ Additional requests instruments

## SESSION 2

CO2	Subcision	<b>Appt Length</b>
Erbium	Microneedling	
1550nm 1927nm	TCA Cross %	<b>TLA Y/N Time</b>
595nm 1064nm	Filler	
BBL	Punch	<b>Quote</b>
RF	Elliptical	
Pico	TAC/ 5 FU	<b>Rx Interval</b>
QS	Botulinum	

Filler Type/ Additional requests instruments

## SESSION 3

CO2	Subcision	<b>Appt Length</b>
Erbium	Microneedling	
1550nm 1927nm	TCA Cross %	<b>TLA Y/N Time</b>
595nm 1064nm	Filler	
BBL	Punch	<b>Quote</b>
RF	Elliptical	
Pico	TAC/ 5 FU	<b>Rx Interval</b>
QS	Botulinum	

Filler Type/ Additional requests instruments

**“Ransomware is the most significant cybercrime threat to the Australian healthcare sector”... \***

***Are you cyber secure?***

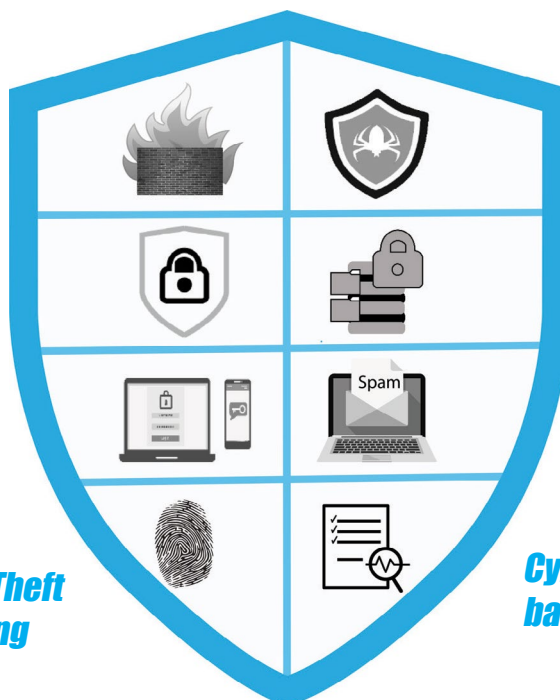
# **DMS Managed Cyber Security**

***Next Gen Firewall Protection with Intrusion Detection and Intrusion Prevention Systems***

***WEB/DNS Filtering Protection***

***Multi Factor Authentication***

***Credential Theft Monitoring***



***Next Gen Pro-Active End Point Detection and Response Protection***

***Immutable Online Backup for Rapid Disaster Recovery***

***Next Gen Email, Phishing, Anti-Spam Protection with regular staff cyber training program***

***Cyber Security Standards based Risk Management Framework***

\*<https://www.cyber.gov.au/acsc/view-all-content/reports-and-statistics/2020-health-sector-snapshot>

## **THE DMS ANTI-MALWARE GUARANTEE:**

With DMS multi-layered Managed Cyber Security, any support time we spend removing malware is completely free.



# Energy-based devices for the treatment of acne scarring

Shobhan Manoharan<sup>1</sup>

1. Brisbane Skin, Newstead, QLD, Australia

Correspondence: Dr Shobhan Manoharan ✉ shobhan@manoharangroup.com.au

Disclosures: none

**OUTLINE:** Acne scarring is the primary adverse sequelae to acne. The advent and progression of energy-based devices, either as sole or as part of multi-modal therapy, has revolutionised the management of this challenging complication.

**KEYWORDS:** acne, energy-based devices, scarring

Manoharan S. Energy-based devices for the treatment of acne scarring. *Opin Prog Cosmet Dermatol* 2022;2(3):66-70.

## Introduction

Acne vulgaris is a common skin condition with a number of physical and emotional sequelae, but arguably the most significant complication in its aftermath is scarring. This affects up to 95% of patients, with 30% categorised as severe.<sup>1</sup> In this era, a number of modalities can be employed to improve scarring, including topical and systemic medications, peels, surgical procedures and injectable agents.

The advent of energy-based devices (EBDs), and their improvements in efficacy and safety profile over time has added further options to the acne scar treatment armamentarium.

The selection of the most appropriate device, or its use in combination therapy, is based on a number of factors including clinical presentation (e.g., skin-type, scar location and morphology), device settings (e.g., wavelength, target chromophore, depth of penetration), and patient factors such as goals, tolerance for discomfort, downtime, and finances.<sup>1</sup>

The aim of this article is to outline the broad groups of EBDs available to treat acne scarring and discuss their utility and limitations.

## Ablative non-fractional lasers

Ablative lasers such as the 2940 nm Erbium-doped yttrium aluminium garnet (Er:YAG) and the 10600 nm carbon dioxide (CO<sub>2</sub>) were traditionally considered gold-standard for acne scarring, and even to this day

may produce excellent results in minimal number of treatments.<sup>2</sup> They work by vaporising the epidermis and a chosen depth of dermis, leading to neocollagenesis and remodelling,<sup>3</sup> and subsequent improvement of atrophic scarring (Figure 1).

They can, however, be associated with extended recovery time (up to 2 weeks), side effects such as pain, oedema, oozing and crusting, and complications such as prolonged erythema and scarring itself.<sup>2,4</sup>

## Ablative fractional lasers

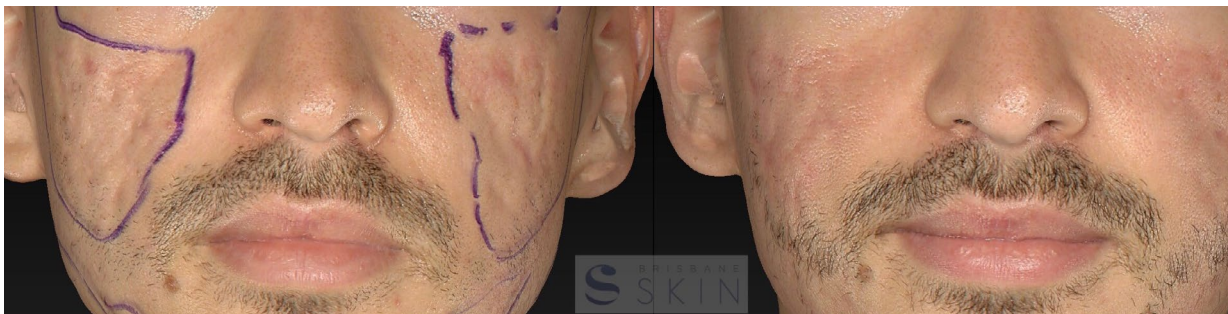The relatively prolonged recovery period and risk of adverse effects with ablative lasers led to the development of ablative fractional lasers (AFL). These lasers work on the theory of fractional photothermolysis, whereby instead of vaporising sheets of tissue, pixilated columnar zones of thermal injury (microthermal treatment zones, MTZ) are created, allowing for more rapid healing through unaffected tissue and the opportunity to treat darker skin types and non-facial areas with reduced complications.<sup>5</sup> Furthermore, AFL also allows for the treatment of hypertrophic or keloid acne scarring, often in combination of injected scar modulating agents (corticosteroids, 5-fluorouracil, botulinum toxin, etc) or laser-assisted drug delivery. Both the CO<sub>2</sub> and Er:YAG lasers have been developed in fractional modes for this purpose.

The ablative fractional CO<sub>2</sub> laser was the device with the most available evidence in acne scarring and achieved improvement in appearance that ranged from modest to excellent in most studies (Figure 2).<sup>6</sup>





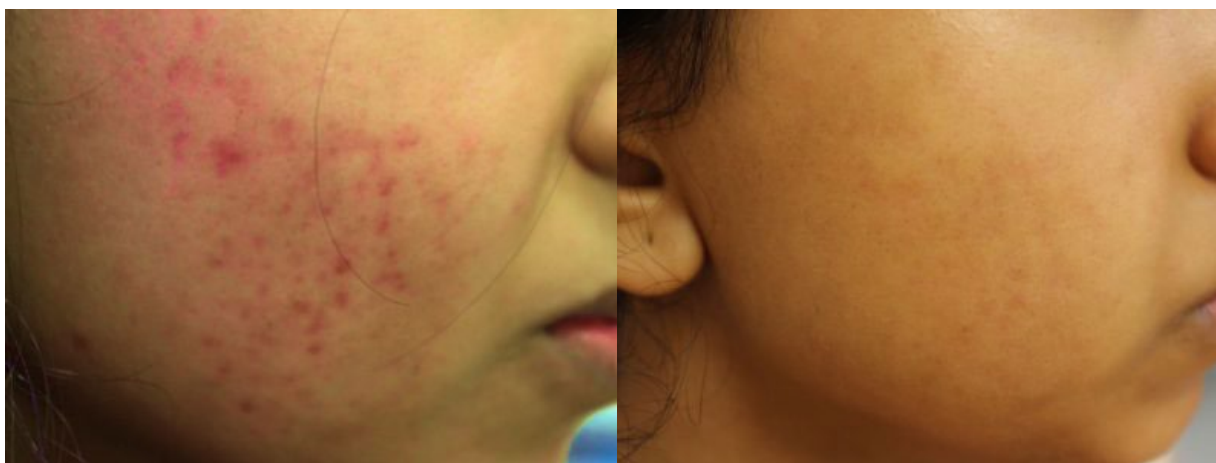
**Figure 1.** Patient treated with one session of subcision and fully ablative CO2 laser resurfacing. 3 months post-treatment



**Figure 2.** Patient after 2 sessions of fractional Erbium:YAG laser treatment in combination with subcision and platelet-rich plasma injections



**Figure 3.** Patient following a series of 4 treatments with the 1550 nm Erbium:glass laser



**Figure 4.** Erythematous acne scarring treated with a series of 4 pulsed-dye laser sessions

Even though this generation of AFLs may be safer than their non-fractional counterparts, they may still be associated with some risk of erythema, dyschromia and scarring. These side effects may be minimised by appropriate patient selection, pre-treatment preparation and post-treatment care, and appropriate device settings.

The general consensus is that for most patients, a series of 2-4 sessions of AFL, spaced at least 1 month apart, would be required for a satisfactory response.<sup>1</sup>

### Non-ablative fractional lasers

Non-ablative fractional lasers (NAFL) cause controlled microcolumns of thermal injury to the dermis while relatively sparing the epidermis, resulting less side effects and shorter recovery periods. They include the 1550 nm Er:doped laser, 1540 nm Er:glass laser, and combination 1550 nm Er:glass/1927 nm Thulium fibre laser.<sup>5</sup>

Downtime is typically 1-2 days as opposed to the 1-2 weeks with ablative systems, with a higher safety margin and the ability to treat all skin types.<sup>1</sup> The trade-off, however, is that results may be more modest, and multiple treatment sessions is the standard. A typical NAFL protocol would be four to eight sessions at monthly intervals (Figure 3).

Neocollagenesis and matrix remodelling occurs with NAFL, but some systems, such as the 1927 nm Thulium fibre laser can clear pigment in atrophic scars.<sup>5</sup> Colouration accentuates scarring and by reducing this, even with modest gains in overall texture, significant improvements in the perception of scarring may be achieved.

### Vascular lasers

Vascular lasers, such as the 585/595 pulsed dye laser (PDL), the 532 nm potassium titanyl phosphate (KTP) laser, and non-coherent light emitting devices such as intense pulsed light (IPL) with a vascular filter, can all be used to treat erythematous acne scarring.<sup>1</sup>

Erythema is often a feature of early acne scars, and proactive intervention with vascular laser may prevent progression to more severe atrophic and hypertrophic scarring.

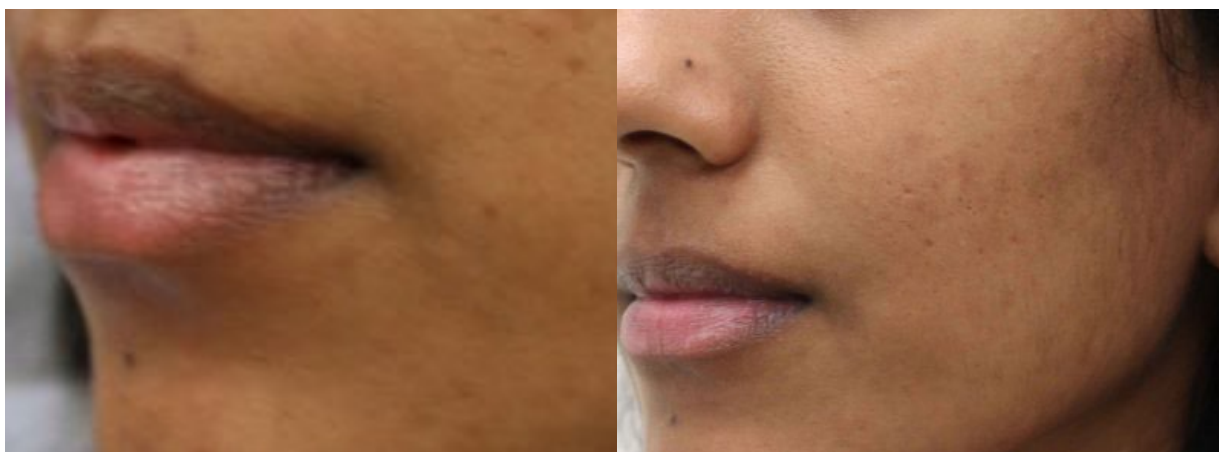Even though they reduce scar-associated erythema, they may also induce wound-healing and collagen remodelling by influencing scar mediators such as transforming growth factor factor-beta isoforms<sup>7</sup> (Figure 4).

Vascular lasers also play a key role in combination with previously mentioned injectable agents as the EBD of choice and second-line treatment for hypertrophic and keloid acne scarring.<sup>1</sup>

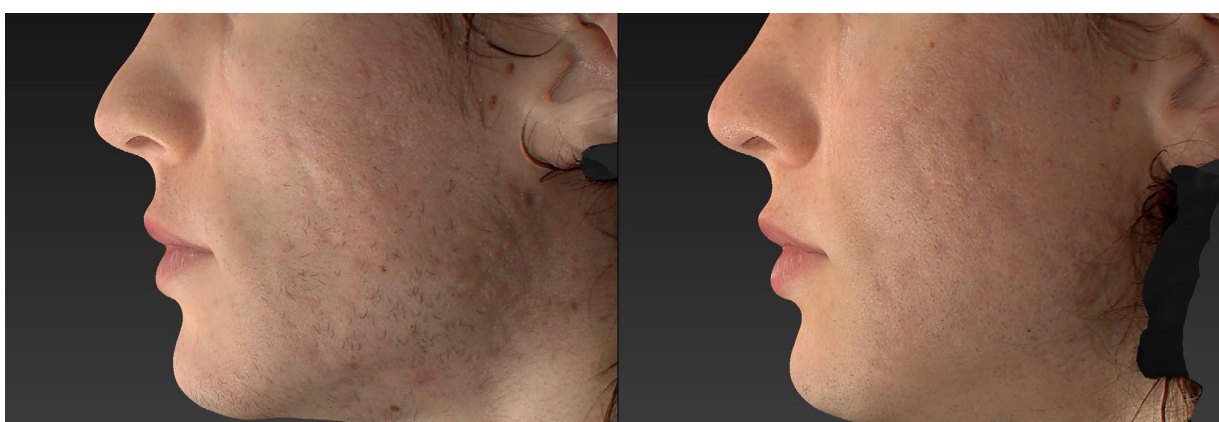
### Short-pulsed (nanosecond and picosecond) lasers

The Q-switched (nanosecond) Nd:YAG 1064 nm laser and picosecond lasers have become the EBDs of choice for macular hyperpigmentation, and milder scarring particularly in patients with skin of colour<sup>1</sup> (Figure 5).

Picosecond lasers are a more novel technology, which now come in varying wavelengths including 1064 nm, 755 nm, 532 nm and 670 nm, produce ultra-short pulse durations and significant photoacoustic as well as photothermal responses. Many also have the ability to



**Figure 5.** Hyperpigmented acne scars treated with 2 sessions of 1064 nm picosecond laser with micro lens array



**Figure 6.** Patient's scar results following 4 treatments with fractional radiofrequency microneedling

produce a fractionated effect by utilising a diffractive lens array, distributing the laser beam into peaks of high fluence surrounded by a low fluence background, resulting in optical breakdown of dermal tissue (laser induced optical breakdown, or LIOB), induction of wound healing and neocollagenesis.<sup>8</sup>

Several published reports have shown mild to moderate efficacy for atrophic acne scarring, with low side effect profile.<sup>1</sup>

## Fractional radiofrequency

Fractional radiofrequency (FRF) is also a more novel technology, with significant evolution over the last few years. In fractional bipolar RF, current flows through the skin between electrode pins or microneedles, resulting in the precise delivery of deep dermal heating to desired depths within the dermis.<sup>1,6,9</sup>

FRF needles may either be insulated or non-insulated, with benefits and disadvantages associated with both.

The insulated form allows for the electrothermal damage to be restricted to the very tip of the needle, minimising collateral damage and relatively sparing the epidermis.<sup>6</sup>

FRF has a promising role as a low downtime treatment option for atrophic acne scars (Figure 6). Patients are generally recommended 4–8 sessions spaced at least 1 month apart to achieve satisfactory results. In the author's opinion, FRF also has a role in the treatment of acne and scarring with a synergistic improvement often seen in both. Additional research will be required to compare its efficacy to NAFL and AFL.<sup>1</sup>

## Other EBDs

There are a few novel, non-laser, non-RF devices currently being investigated, and further studies will need to ascertain their efficacy in the treatment of acne scarring.

The Tixel™ (Novoxel Ltd.) is a fractional, non-ablative, thermomechanical system, combining thermal



conduction with motion. Energy is delivered via small titanium pyramids heated to 400°C. Limited evidence is available at this point for the treatment of acne scars, but it has been utilised in skin rejuvenation, hypertrophic scars and for drug delivery. Results may be modest, with experienced users suggested less than 20% improvement after a course of treatment.<sup>1</sup>

## Conclusions

There are a number of EBDs utilised in the treatment of acne scars, both established and novel. Ablative lasers (non-fractional and fractional) seem to achieve the highest efficacy, but are associated with significant pain and downtime, and risk of complications. NAFL and FRF enables safer treatments with less recovery time, but also more modest improvements.

Vascular lasers and short-pulsed lasers are often used in combination to target specific features of acne scars.

Novel treatments such as Tixel™ require further studies to understand their position within this field of treatment.

Most acne scars inevitably require combination therapy, and EBDs position themselves a vital cog in the treatment plans of many, alongside topical and systemic agents, injectables, peels, and surgical techniques.

## References

1. Salameh F, Shumaker PR, Goodman GJ, et al. Energy-based devices for the treatment of acne scars: 2022 International consensus recommendations. *Lasers Surg Med.* 2022;54(1):10-26.
2. Goodman GJ. Treatment of acne scarring. In: Zouboulis C, Katsambas D, Kligman AM (eds) *Pathogenesis and Treatment of Acne and Rosacea*. Heidelberg: Springer Berlin;2014: 527-536.
3. Alster TS, Tanzi EL, Lazarus M. The use of fractional laser thermolysis for the treatment of atrophic scars. *Dermatol Surg.* 2007; 33(3):295-299.
4. Majid I, Imran S. Fractional CO2 laser resurfacing as monotherapy in the treatment of atrophic facial acne scars. *J Cutan Aesthet Surg.* 2014;7(2):87-92.
5. Sadick N, Cardona A. Laser treatment for facial acne scars: A review. *J Cosmet Laser Ther.* 2018;20(7-8):425-435.
6. Kravvas G, Al-Niaimi F. A systematic review of treatments for acne scarring. Part 2: Energy-based techniques. *Scars, burns heal.* 2018 Aug 16;4:2059513118793420.
7. Seaton E, Mouser PE, Charakida A, et al. Investigation of the mechanism of action of non-ablative pulsed-dye laser therapy in photo rejuvenation and inflammatory acne vulgaris. *Br J Dermatol.* 2006;155:748-55.
8. Huang CH, Hsieh FS, Chang HC, et al. 755nm picosecond laser for facial atrophic scar – case reports of long-term clinical efficacy following up. *J Cosmet Dermatol.* 2019;18:778-82.
9. Arruda S, Swearingen A, Medrano K, et al. Subject satisfaction following treatment with nanofractional radiofrequency for the treatment and reduction of acne scarring and rhytids: A prospective study. *J Cosmet Dermatol.* 2021;20:3475-3481.

LEARN WHY MORE DERMATOLOGY  
PRACTICES AROUND AUSTRALIA  
ARE INVESTING IN THIS  
INNOVATIVE TECHNOLOGY

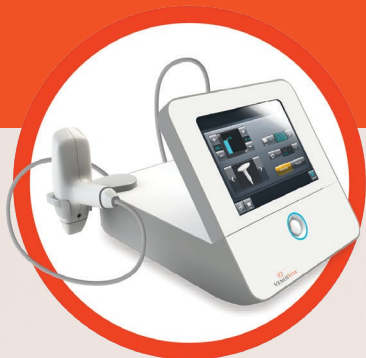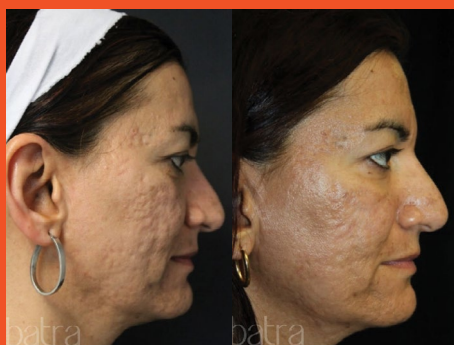## THE GO TO DEVICE FOR ACNE AND SURGICAL SCARRING

Highly customizable parameters  
for a wide range of skin conditions

Safe for all skin types\*

BEFORE

AFTER



# VENUSVIVAMD

Venus Viva™ MD is a highly effective and customizable skin ablation and resurfacing device, and it now comes with two tip options for treating a range of mild to severe skin conditions. Treat milder skin texture irregularities with the 160 pin tip, or treat more severe acne scars, scars, and deep rhytides with the 80 pin tip. This device uses NanoFractional Radio Frequency (RF) technology, offering patients a safer, lower downtime, lower risk alternative to traditional skin resurfacing options, while providing equal results. A published clinical study showed that 100% of patients rated their satisfaction with the results of their NanoFractional RF™ treatments as "Excellent," "Very Good," or "Good."

\*The Venus Viva™ MD is cleared by TGA, FDA, and Venus Viva™ (using the Viva™/Viva™ MD applicators) is licensed for the use in dermatological procedures requiring ablation and resurfacing of the skin.

Before and After images and consent supplied by Dr Sonia Batra

Call Blake Williams on  
M. 0418 119 344 or visit  
[www.venusconcept.com](http://www.venusconcept.com) to  
find out more

**VENUSCONCEPT**  
delivering the promise


# Are we too reliant on energy-based devices for the treatment of acne scarring?

Davin Lim<sup>1</sup>

1. Cutis Clinic, Queensland, Australia

Correspondence: Davin Lim [info@drdavinlim.com](mailto:info@drdavinlim.com)

Disclosures: none



[CLICK IMAGE TO LINK TO VIDEO](#)

DURATION\_01:41

**OUTLINE:** Over the past two decades the art and science of acne scar revision has undergone a significant change, influenced by a myriad of new energy devices. With new devices developing at a frantic pace, perhaps we have forgotten the value of manual skill sets, relying on fire and not preset solutions on these devices.

Revision treatments should be based on the patient's scar morphology, severity, skin type, downtime, age, time frame, finances and insight. This algorithmic approach may employ energy-based devices, manual non-energy-based treatments, or commonly a combination of both (Figure 1). With the growing body of evidence, there are however, certain scar patterns that lend themselves to manual non-energy-based therapies over energy devices. Methods include surgical subcision, excision, elevation, focal peels, microneedling, and volume replacement with dermal fillers.

**KEYWORDS:** acne scars, CROSS, TCA, subcision

Lim D. Are we too reliant on energy-based devices for the treatment of acne scarring? *Opin Prog Cosmet Dermatol* 2022;2(3):72-74.

## What scar signatures are amenable to manual methods of revision?

Though the Jacob classification<sup>1</sup> of scar revision is the most widely used classification of acne scarring, a simple algorithm is to class scars as superficial, deep or a combination of these depths.

Deep acne scar patterns include ice pick, rolling and atrophic variants. Ice pick scars are one of the most common forms of atrophic scarring.<sup>2</sup> Despite advances in laser technology, ice pick scarring is often refractory to treatment. The solution? Manual based methods such as trichloroacetic acid (TCA) or phenol chemical reconstruction of skin scars (CROSS) with wooden applicators, insulin syringe delivery or fine paint brushes are the treatment methods of choice for ice pick scars (Figure 2).<sup>3,4</sup> These somewhat "primitive" techniques provide precise targeting of these scar variants, minimizing collateral damage to the surrounding tissue, optimizing results, and reducing treatment cost for patients.

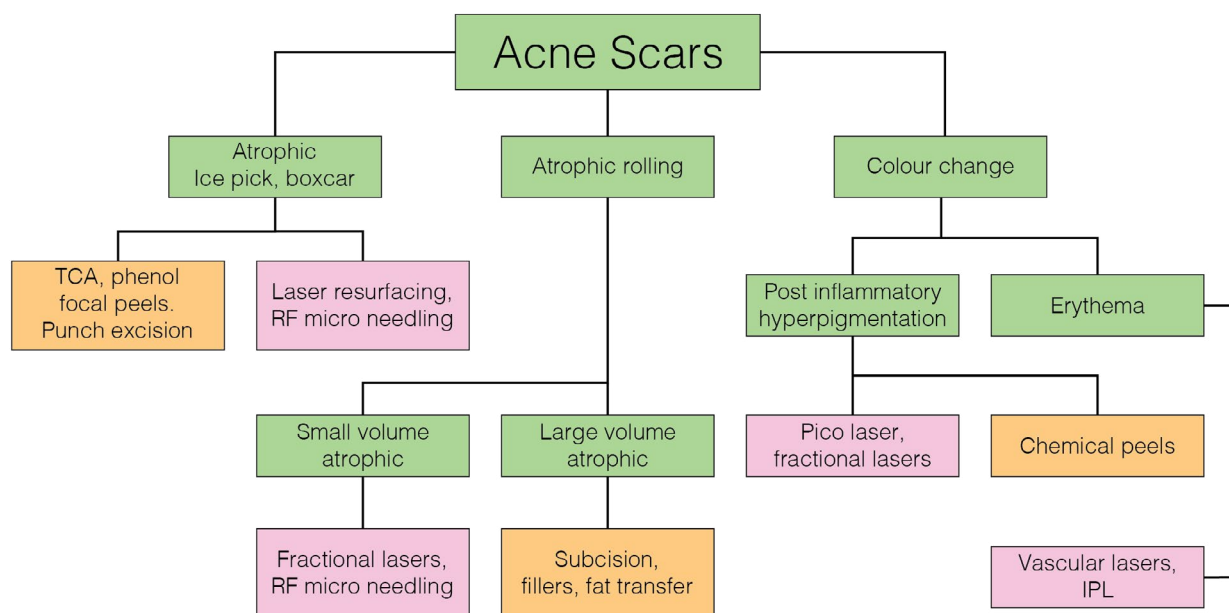
Another treatment modality for icepick scars that provides more rapid results than CROSS technique

is simple punch excision (Figure 2).<sup>5</sup> The author repurposes follicular extraction unit (FUE) punches in sizes ranging from 0.6 to 1.5 mm. These punches retain their sharp edge even after 100 excisions. Punch biopsies on the other hand blunt after 3-8 excisions.

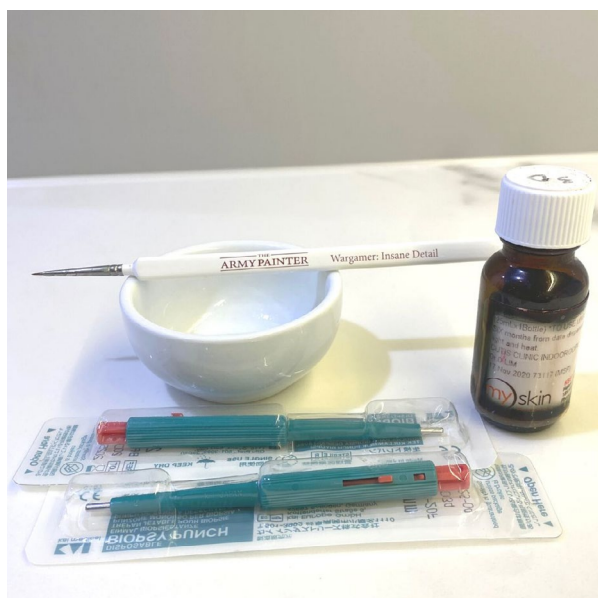Superficial scars such as linear, broad and classic boxcar scarring are amenable to procedures such as TCA or phenol croton oil. We have described a simple paint brush technique utilizing undyed fine brushes to effectively and safely treat these scar variants.<sup>4</sup> With focal application of deep peeling agents we minimize collateral damage to the surrounding tissue, which in turn reduces side effects and speeds up recovery. Additionally, the use of focal peels reduces procedural costs for the patient.

Subcision is a minimally invasive surgical treatment for rolling and atrophic acne types. This method was first described by the Orentreich brothers in 1995 using tri-beveled hypodermic needles.<sup>6</sup> Since its inception, a plethora of instruments have been used, ranging from blunt cannulas, larger hypodermic needles to cutting blades such as Nokor needles and novel instruments (Figure 3).<sup>7-9</sup> These instruments are introduced into






**Figure 1.** Acne scar repair algorithm for atrophic, rolling and colour scars



**Figure 2.** Focal TCA application and punches are simple, yet highly effective treatment methods for ice pick and boxcar acne scars



**Figure 3.** Cannulas and needles are simple instruments to transect fibrotic acne scars

the deep dermis and hypodermis parallel to the skin's surface. Rapid repetitive back and forth motion of the instrument dissects fibrotic scar tissue within these planes, in turn producing elevation of depressed areas in addition to stimulation of neocollagenesis.

Energy-based devices such as lasers and radiofrequency assisted microneedling rely on vertically delivered 'chance events' to disrupt deep scar tissue, in turn breaking down fibrosis and stimulating neocollagenesis.<sup>10</sup> In comparison, a clinician trained in

subcision will identify fibrotic areas as their instrument passes through the deep dermal and subcutaneous layers of skin. With practice, a clinician deft in manual techniques will understand the varying resistance patterns of fibroseptal networks, retaining ligaments and atrophic, or conversely fibrotic scar patterns. With skill and precision, they can navigate their way through scar tissue, triangulating entry points to geometrically release underlying tethering with more predictability than energy devices.

The use of soft tissue filler for correction of atrophic scars was first reported in 1980, preceding US FDA approval for isotretinoin.<sup>11</sup> They remain invaluable in the management of rolling and boxcar acne scars with various studies showing improvements ranging from 33 to >70%.<sup>12,13</sup> They provide a greater predictability in the treatment of larger volume atrophic rolling scars compared to energy devices, with less adverse events, immediate results and virtually no downtime. Various techniques have been reported using needles and cannulas.<sup>13-15</sup> Filler classes employed for scar revision include recombinant hyaluronic acid, calcium hydroxyapatite, polymethylmethacrylate and poly-L-lactic acid.<sup>15-17</sup>

Though I am an enthusiastic optimist looking forward to newer energy devices, we must not forget the time-tested, often simple in-office procedures. We have at our disposal readily available instruments such as cannulas, needles, and punches which we can repurpose to revise scar tissue. Procedures such as focal chemical peels and soft tissue fillers can add to our skill sets.

In clinical practice, it is a combination of procedures that will yield the best outcomes. When the scar signature calls for non-energy-based methods, answer it with the methods you have learned and the skill sets which you have mastered. It is imperative we continue to perform and evolve these methods and not solely rely on the latest, newest device.

## References

1. Jacob CI, Dover JS, Kaminer MS. Acne scarring: a classification system and review of treatment options. *J Am Acad Dermatol*. 2001;45(1):109-17.
2. Gozali MV, Bingrong Z. Effective treatments of atrophic acne scars. *J Clin Aesthet Dermatol*. 2015;8(5):33-40.
3. Agarwal N, Gupta LK, Khare AK, Kuldeep CM, Mittal A. Therapeutic response of 70% trichloroacetic acid CROSS in atrophic acne scars. *Dermatol Surg*. 2015;41:597-604.
4. Sun C, Lim D. Trichloroacetic Acid Paint for Boxcar and Polymorphic Acne Scars. *Dermatol Surg*. 2022;48(2):214-8.
5. Grevelink JM, White VR. Concurrent use of laser skin resurfacing and punch excision in the treatment of facial acne scarring. *Dermatol Surg*. 1998;24(5):527-30.
6. Orentreich DS, Orentreich N. Subcutaneous incisionless (subcision) surgery for the correction of depressed scars and wrinkles. *Dermatol Surg*. 1995;21(6):543-9.
7. Goodman GJ. Therapeutic undermining of scars (Subcision). *Australas J Dermatol*. 2001;42(2):114-7.
8. Barikbin B, Akbari Z, Yousefi M, Dowlati Y. Blunt blade subcision: an evolution in the treatment of atrophic acne scars. *Dermatol Surg*. 2017;43:S57-S63.
9. Al-Khenaizan S. Nokor needle marking: a simple method to maintain orientation during subcision. *J Drugs Dermatol*. 2007;6(3):343.
10. Alster TS, Tanzi EL, Lazarus M. The use of fractional laser photothermolysis for the treatment of atrophic scars. *Dermatol Surg*. 2007;33(3):295-9.
11. Stegman SJ, Tromovitch TA. Implantation of collagen for depressed scars. *J Dermatol Surg Oncol*. 1980;6:450-3.
12. Rkein A, Ozog D, Waibel JS. Treatment of atrophic scars with fractionated CO2 laser facilitating delivery of topically applied poly-L-lactic acid. *Dermatol Surg*. 2014;40(6):624-31.
13. Goodman GJ, Van Den Broek A. The modified tower vertical filler technique for the treatment of post-acne scarring. *Australas J Dermatol*. 2016;57:19-23.
14. Mohammed GF, Al-Dhubaibi MS. Triple steps acne scar revision technique: A new combination therapeutic modality for atrophic acne scars. *J Cosmet Dermatol*. 2022;21(10):4659-68.
15. Karnik J, Baumann L, Bruce S, Callender V, Cohen S, Grimes P, et al. A double-blind, randomized, multicenter, controlled trial of suspended polymethyl methacrylate microspheres for the correction of atrophic facial acne scars. *J Am Acad Dermatol*. 2014; 71:77-83.
16. Sapra S, Stewart JA, Mraud K, Schupp R. A Canadian study of the use of poly-L-lactic acid dermal implant for the treatment of hill and valley acne scarring. *Dermatol Surg*. 2015;41:587-94.
17. Beer K. A single-center, open-label study on the use of injectable poly-L-lactic acid for the treatment of moderate to severe scarring from acne or varicella. *Dermatol Surg*. 2007;33 (Suppl. 2):S159-67.

# Management of elevated acne scars

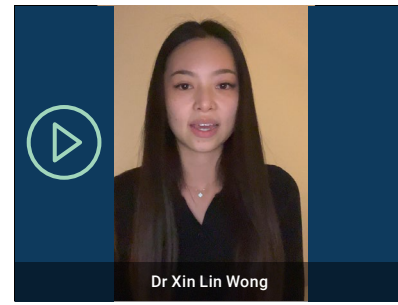
Xin Lin Wong<sup>1,2</sup>, Stephen Shumack<sup>1,2</sup>

1. University of New South Wales, Sydney, NSW, Australia

2. Royal North Shore Hospital, Sydney, NSW, Australia

Correspondence: Xin Lin Wong [xinlin.wong1@gmail.com](mailto:xinlin.wong1@gmail.com)

Disclosures: none



CLICK IMAGE TO LINK TO VIDEO

DURATION\_00:48

**OUTLINE:** Elevated acne scars are due to increased collagen formation and can cause significant psychosocial morbidity. Diagnosis of scar type and use of scar-specific treatment is crucial in achieving effective cosmetic outcomes. This article will discuss the three main subtypes of elevated acne scarring: hypertrophic, keloid and papular acne scars. Additionally, the article will overview established and recent advances in treatment options, including the use of injectables such as triamcinolone, 5-fluorouracil and botulinum toxin; energy devices; and laser assisted drug delivery.

**KEYWORDS:** acne scars, hypertrophic acne scars, keloid acne scars, papular acne scars

Wong XL, Shumack S. Management of elevated acne scars. *Opin Prog Cosmet Dermatol* 2022;2(3):75-81.

## Introduction

Elevated acne scarring consists of keloid, hypertrophic and papular scars. They are thought to be due to an imbalance between increased fibroblast activity and decreased collagenase activity. They may be a consequence of inflammatory acne (Figure 1) but can also develop after burns, trauma, piercings or surgery. Although the majority of acne scarring is atrophic in nature,<sup>1</sup> there is an increased risk of hypertrophic and keloid scarring in genetically susceptible individuals (males, Asian, African-American descent) as well as in particular anatomical locations (ear lobe, trunk, mandible region). Treatment of these scars is important not only cosmetically, but for quality of life as they may potentially cause pain, pruritus and limit range of movement. If the scar is asymptomatic and very

mild it is reasonable to educate the patient of the high probability of natural remission and delay cosmetic treatment. In the case of symptomatic or severe elevated acne scarring, this article provides a structured guide and approach to management.

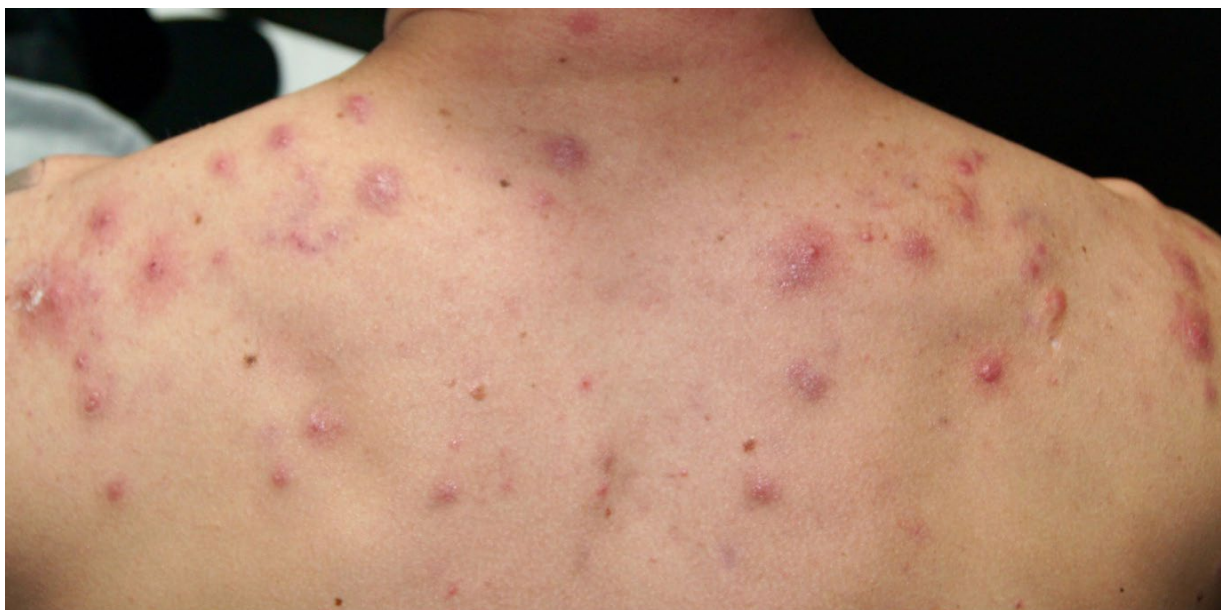## Scar types

**Hypertrophic acne scars** are raised, pink, firm papules that are confined to the area of initial insult. Its severity (Grade 2-4) can be classified by the grading algorithm proposed by Goodman-Baron et al (Table 1). Typically, hypertrophic scars will often regress and flatten as they mature over a period of 12-24 months. Treatments include silicon sheeting, injectables, laser, laser-assisted drug delivery and combination therapy.

**Table 1.** Grading algorithm for elevated acne scarring with a modified Goodman-Baron scar scale, 2006<sup>2</sup>

Grade	Description
1	<b>Abnormally coloured macular disease:</b> erythematous, hyperpigmented or hypopigmented flat marks visible at any distance
2	<b>Mild but abnormally contoured scarring:</b> mild hypertrophy that may not be obvious at social distances of 50 cm or greater and may be adequately camouflaged with makeup, the normal shadow of a shaved beard in men or normal body hair if extra-facial
3	<b>Moderately abnormally contoured disease:</b> moderate hypertrophic scarring that is obvious at social distances of 50 cm or greater and is not covered easily
4	<b>Severely abnormal contoured disease:</b> severe hypertrophic scarring that is obvious at social distances greater than 50 cm, is not covered easily.





**Figure 1.** Inflammatory acne on the upper back evolving into elevated scar morphology

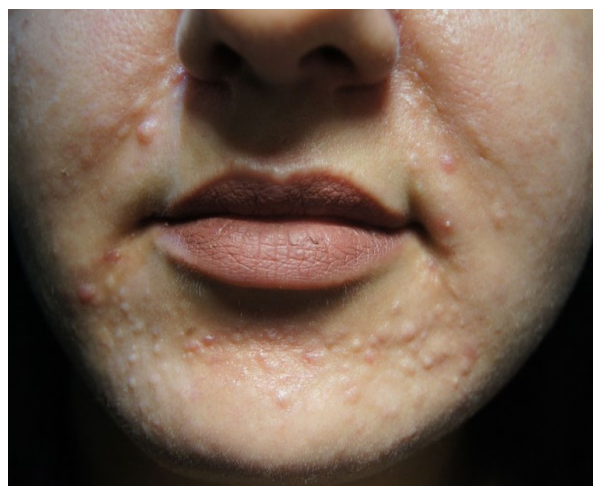
**Keloid scars** are red to purple papules or nodules. Unlike hypertrophic scarring, this scar type extends beyond the original wound border. They can occur spontaneously or following minor insults and are more challenging to manage than hypertrophic scars. Patients will often report accompanying pruritus, allodynia, and dysesthesia as well as a limited range-of-movement. Keloid scars tend to grow without regression due to ongoing fibroblast hyperactivity making it less responsive to traditional therapy and challenging to manage. It is thought that mechanical tension from sites that are exposed to frequent movement may cause excessive collagen production and hence it predominantly affects sites of mobility including the jaw, chest, shoulders and back.<sup>3,4</sup> Treatment is often multimodal (injectables, pressure therapy, surgical excision) due to its tendency to recur and must be repeated over time for adequate effect.

**Papular acne scars** appear as soft fibrous hypopigmented or skin-coloured cobblestone-like papules (Figure 2). They range from 2–4 mm in diameter and commonly afflict the nose, chin and upper back with an increased proclivity for males.<sup>4,5</sup> Although papular scarring is rare there is an increased prevalence in patients who develop keloid scarring.<sup>4</sup> This scar type is similarly difficult to manage.

## Management

### Scar directed therapy

The general basis of treatment for all hypertrophic scar directed therapy is to reduce or arrest fibroblast proliferation which reduces collagen synthesis.



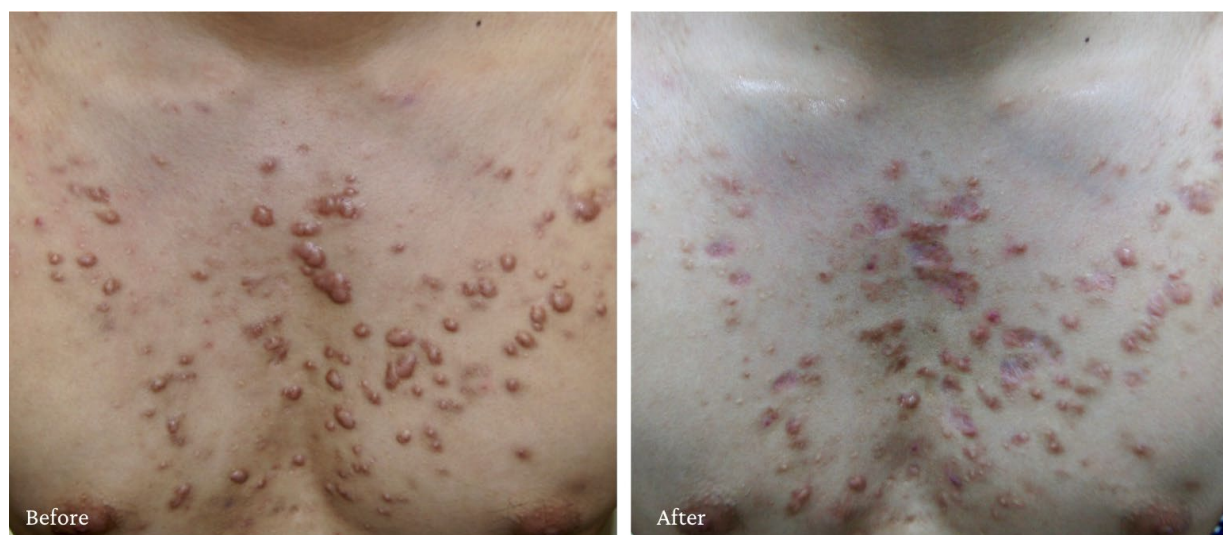**Figure 2.** Papular acne scarring in a perioral distribution

### Silicone

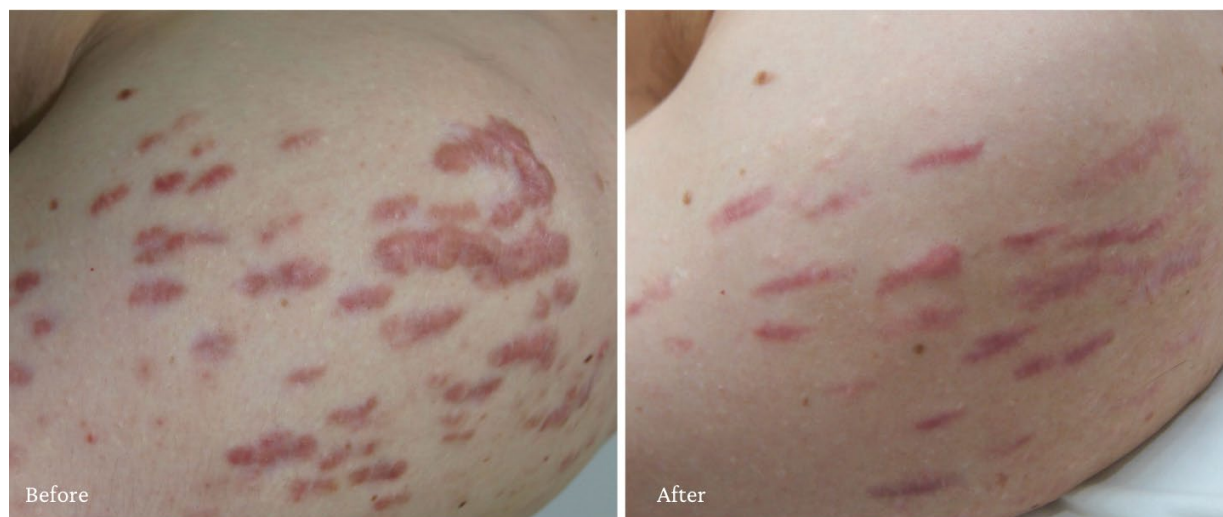Silicone gel or sheets have been widely used for the management of hypertrophic scarring given its non-invasive nature and safety profile. It is thought that the combination of pressure, occlusion and increased hydration inhibits fibroblast activity, prevents wound desiccation and offers external scar protection. It is recommended to be worn 12–14 hours per day for a minimum of 1 month to achieve therapeutic outcomes.<sup>6,7</sup>

### Compression therapy

Compression therapy is thought to be effective due to decreased blood flow towards the scar. It is both cost-effective and non-invasive but in practice, it is limited to the auricular region due to its easy applicability to this site. It is often incorporated in the



**Figure 3.** Hypertrophic and keloid scars on the upper chest before (left) and 6 weeks after initial intralesional triamcinolone injections (20-40 mg/mL)



**Figure 4.** Keloid scars of the left shoulder before and after multiple sessions of pulsed dye laser (595 nm 7 mm 1.5 ms 7 J/cm<sup>2</sup>) and intralesional 5-FU (50 mg/mL):triamcinolone 20-40 mg/mL (3:1 ratio)

post-excision treatment of severe auricular keloids for this reason. If employed, pressure devices should be worn continuously for 8 to 24 hours a day for the first 6 months of scar healing. It is important to educate patients that success rate depends very much on compliance.<sup>8</sup> The focal and scattered distribution of elevated acne scars on the face and torso tends to limit the usefulness of this option in our target population.

### Injectables

Injectable therapies are widely used for the treatment of hypertrophic scarring, and the most useful. These include corticosteroids and cytotoxic agents (5-fluorouracil, bleomycin). Patients should be warned that due to the dense nature of the scar, the injection process will be uncomfortable.

**Intralesional corticosteroids** are widely used for hypertrophic scars and are often the first-line treatment for keloid scarring. As well as decreased fibroblast activity it reduces inflammatory mediators leading to its beneficial effects.<sup>6</sup> Triamcinolone acetonide (TAC) is the most frequently used agent and can be injected directly into the scar every 4 to 6 weeks with concentrations ranging from 10-40 mg/mL depending on scar thickness (Figure 3).<sup>7</sup> Complications include localised dermal atrophy, ulceration, hypopigmentation or telangiectasia if drug concentration and delivery is not well controlled.<sup>9</sup> Injections may be repeated until the scar flattens and pruritus and pain-related symptoms subside.

**5-Fluorouracil (5-FU)** is a cytotoxic agent which induces apoptosis in hyperproliferative and metabolically fibroblastic cells.<sup>9</sup> 5-FU is contraindicated in pregnant and bone marrow suppressed patients and careful history-taking should be elicited to ensure that this is not missed. Although it can be used as a monotherapy at 50 mg/mL (0.1 to 0.3 mL in total per scar) it is more commonly used in conjunction with TAC for scar therapy.<sup>10</sup>

**TAC:5-FU** has been found to be a synergistic combination therapy for hypertrophic acne scarring. It appears to be more efficacious than TAC and 5-FU monotherapy and has a safer side effect profile as reduced doses are required when used in conjunction.<sup>9,11,12</sup> It is commonly recommended for intralesional injections to start with higher concentrations of TAC (40 mg/mL) before incremental down titration to 10 mg/mL as the bulk of the scar decreases. Therefore, injections can start at 40 mg/mL TAC in combination with 5-FU (TAC:5-FU ratio range of 1:9 to 1:3, maximum 0.1 mL total per scar) every 4–6 weeks until the scar becomes flat, soft and symptom-free (Figure 4).<sup>13</sup>

**Bleomycin** is a cytotoxic agent which inhibits collagen synthesis by targeting rapidly dividing fibroblasts. It is administered through topical application after the creation of multiple superficial puncture wounds to aid absorption.<sup>14</sup> This process is typically repeated from 2 weeks to 4 months depending on rate of response.<sup>15</sup> Its efficacy is similar to TAC monotherapy however it has been found to cause a high rate of hyperpigmentation.<sup>7,15</sup> Appropriate patient selection is pertinent as application will cause significant pain which can persist for up to 72 hours and patients should be thoroughly warned of this adverse effect.

**Botulinum toxin (BTX)** is a potent neurotoxin that reduces fibroblast proliferation and chemoinmobilises striated muscle. It aids in both hypertrophic and keloid scar treatment by reducing the tensile forces exerted by neighbouring muscle mass. It is a reported alternative to TAC as it is equally efficacious and bears less adverse effects conferring increased patient satisfaction.<sup>16</sup> For the treatment of hypertrophic scarring 2.5 U/cm<sup>3</sup> can be used every 4 weeks for up to 3 months. Higher doses may be used for keloid scars (5–35 IU/cm<sup>3</sup>) which can be repeated every 4 to 8 weeks.<sup>17</sup> BTX is a favourable modality for the treatment of keloids as it has been found to aid in the reduction of keloid volume, height and vascularity as well as alleviate symptoms of keloid associated pain and itch.<sup>17,18</sup> Cost and product familiarity in the scar context are barriers to wider uptake of BTX for elevated scars.

### Cryotherapy

Cryotherapy causes direct vascular injury leading to anoxia and tissue necrosis. It is used in the treatment

of smaller, younger scars. Depending on response, treatment can range from between two to 10 treatments every 3–4 weeks to achieve adequate cosmetic outcomes. Complications include immediate blistering, pain and erythema with longer-term risks of dermal atrophy that can lead to permanent dyspigmentation.<sup>9</sup> Cryotherapy prior to keloid injections offer the benefits of cold analgesia, easier injection (lower plunger pressure) because of scar oedema, and improved drug dispersion in scar tissue.

### Radiotherapy

Radiotherapy has been used in the management of resistant hypertrophic scars and keloids in older patients due to its carcinogenic risk. It inhibits fibroblast proliferation and collagen synthesis at total doses of 15–30 Gy.<sup>9</sup> It is effective at reducing pain and pruritus and is often used in conjunction with ILC. This treatment option can be broached with the patient however would warrant a formal referral to a dermatologist and radiation oncologist for ongoing management.

### Surgical excision

Surgical excision is generally considered a last resort that is only warranted in cases of severe mature keloids however must be part of a multimodal preventative approach (compression therapy, ILC, 5-FU, BTX) due to the high likelihood of recurrence.<sup>19</sup> Surgical closure must be achieved with minimal tension and thus we recommend a referral to a dermatologist or plastic surgeon in this setting.<sup>7</sup>

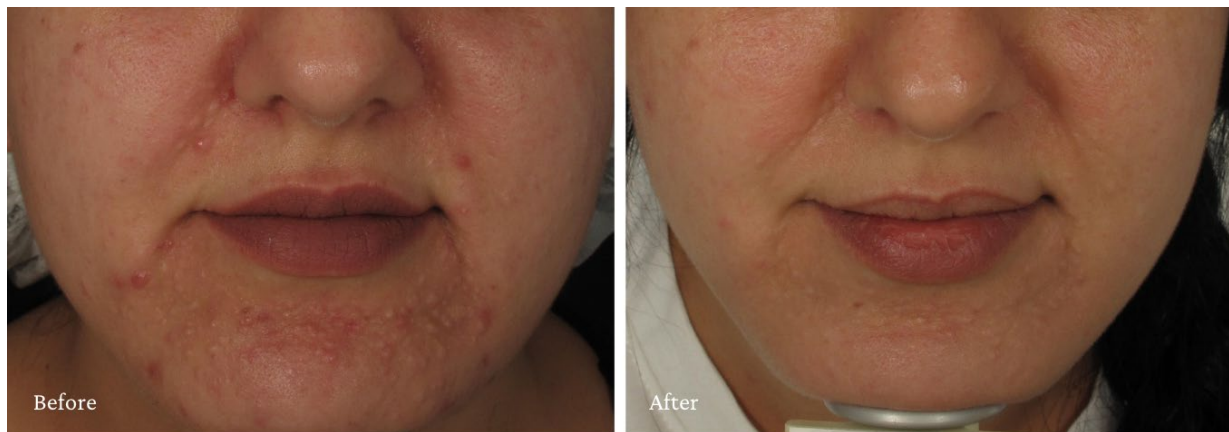### Needle guided radiofrequency ablations

Needle guided radiofrequency ablations has been recently reported for papular acne scars. The central portion of the scar is heated via high frequency alternative electrical currents causing contraction of dermal tissue and flattening of elevated scar tissue.<sup>5</sup> There is no damage to the overlying epidermis and hence it can be used in all skin types.<sup>13</sup> The lesion is first infiltrated with local anaesthetic before a 27-gauge needle is inserted 1–2 mm into the centre of the scar. The radiofrequency probe is then placed on the proximal uninserted portion of the needle and low-power coagulation mode is activated for 1–2 seconds whilst the needle is still penetrated within the scar tissue. It is important that coagulation mode is terminated prior to needle removal to reduce the risk of superficial burns to the epidermis.<sup>5,20</sup> The procedure can be repeated at 4 weeks for up to two sessions for better results.<sup>13</sup>

### Energy-based devices

**Non ablative laser** has been shown to induce collagenolysis and reduce scar fibrosis. It allows for preservation of the epidermis by specifically targeting oxyhaemoglobin within the dermis and is therefore effective against erythematous elevated acne scarring.<sup>21</sup>





**Figure 5.** Papular acne scars before and after spot Er:YAG resurfacing and application of triamcinolone 20 mg/mL by fractional CO<sub>2</sub> laser assisted drug delivery

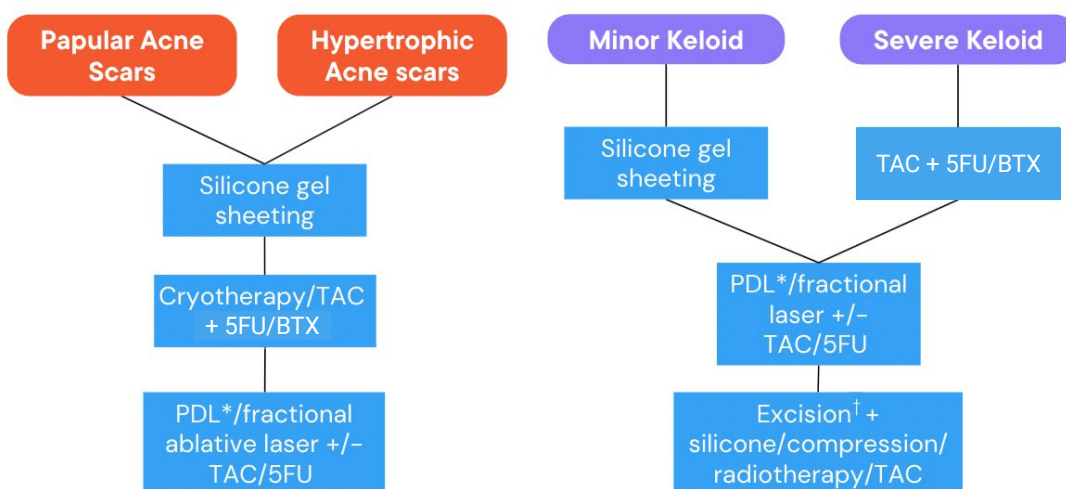
**Pulsed dye laser (PDL) 585–595 nm** has been found to aid in scar management by decreasing vascularity. It is best suited for lighter skin types due to the risks of hyperpigmentation in darker skin types. It is commonly recommended to start with 0.45 ms pulses at 4.5–5.5 J/cm<sup>2</sup> (10 mm spot) or 6–7.5 J/cm<sup>2</sup> (7 mm spot) over the surface of the scar repeated every 6 to 8 weeks for a maximum of three treatments.<sup>8,22</sup> Patients should adhere to strict sun protection to reduce dyspigmentation during the recovery phase.

**Long-pulsed 1064 nm neodymium-yttrium-aluminium-garnet (Nd:YAG)** in contact mode using 0.25 ms pulses at 65–75 J/cm<sup>2</sup> (5 mm spot) every 3 to 4 weeks has also been found to be effective for hypertrophic scarring and for a proportion of patients with keloid scarring.<sup>21,23</sup>

**Ablative laser** is used as a resurfacing tool to recontour and rehabilitate hypertrophic and papular acne scarring. Like PDL there is an increased risk of hyperpigmentation in darker skin types and it should be used with caution in this population group. Both fractional carbon dioxide (CO<sub>2</sub>) 10,600 nm laser and erbium-doped yttrium aluminium garnet (Er:YAG) 2940 nm laser in pulsed or fractional settings have been found to be useful.<sup>24</sup> We recommend incorporating laser assisted delivery of TAC to further improve the appearance of elevated scars (Figure 5).

**Laser-assisted drug delivery (LADD)** is a technique that can enhance the delivery of topical therapies for challenging hypertrophic acne scars including keloids. It is known that cutaneous bioabsorption of topical drugs is limited to 1–5% due to the presence of the stratum corneum.<sup>25</sup> Ablative fractional laser creates

### Treatment algorithm



**Figure 6.** Recommended treatment algorithm

\* Useful for erythematous scars and steroid-induced telangiectasias

† Excision of keloids has a high rate of recurrence and may lead to a potentially worse outcome

precise microscopic vertical zones of ablation which can aid in uniform drug distribution past the stratum corneum into the dermis.<sup>26</sup> This method of delivery is becoming increasingly popular amongst clinicians as it synergistically combines the benefits of ablative laser with a chosen topical drug.<sup>26</sup> The current evidence supports the use of ablative fractional laser with TAC and 5-FU.<sup>19,25-28</sup>

**TAC:** When using TAC it is most commonly recommended to perform a low density pass (5-15% coverage) of a fractional ablative laser (CO<sub>2</sub> or Er:YAG) followed by TAC suspension at 10-40 mg/mL every 4 weeks for 3 to 5 sessions for the treatment of stubborn keloids.<sup>26, 27</sup> Where clinically indicated, LADD with topical TAC may be preferred over intralesional injections as it confers less pain, delivers drugs more uniformly, minimises risk of adverse effects, reduces rates of recurrence and is equally as effective.<sup>19,26,27</sup>

**5-FU:** The current literature suggests a similar application of fractional ablative laser followed by topical 5-FU (5%) immediately after the session and once more during the week. This was performed every 4 weeks for eight sessions and was found to be more efficacious than 5-FU topical monotherapy for the treatment of severe hypertrophic scars and keloids.<sup>25,28</sup>

**BTX:** There is also promising new evidence to suggest that monthly topical application of 5U/0.1 mL of BTX after three passes of CO<sub>2</sub> laser is more effective than intralesional BTX alone however more studies are needed for scientific validation.<sup>29</sup>

## Conclusion

Hypertrophic, keloid and papular acne scarring can significantly impact cosmesis and quality of life. As discussed, treatment options can be utilised as monotherapy or may be combined for synergistic effect. Treatment regimens should be based on careful assessment of scar subtype and consideration of patient skin type before commencement. It is generally recommended to start with the least invasive therapies first, but combination therapy will often be needed to optimise results in this challenging group of scars.

## Acknowledgement

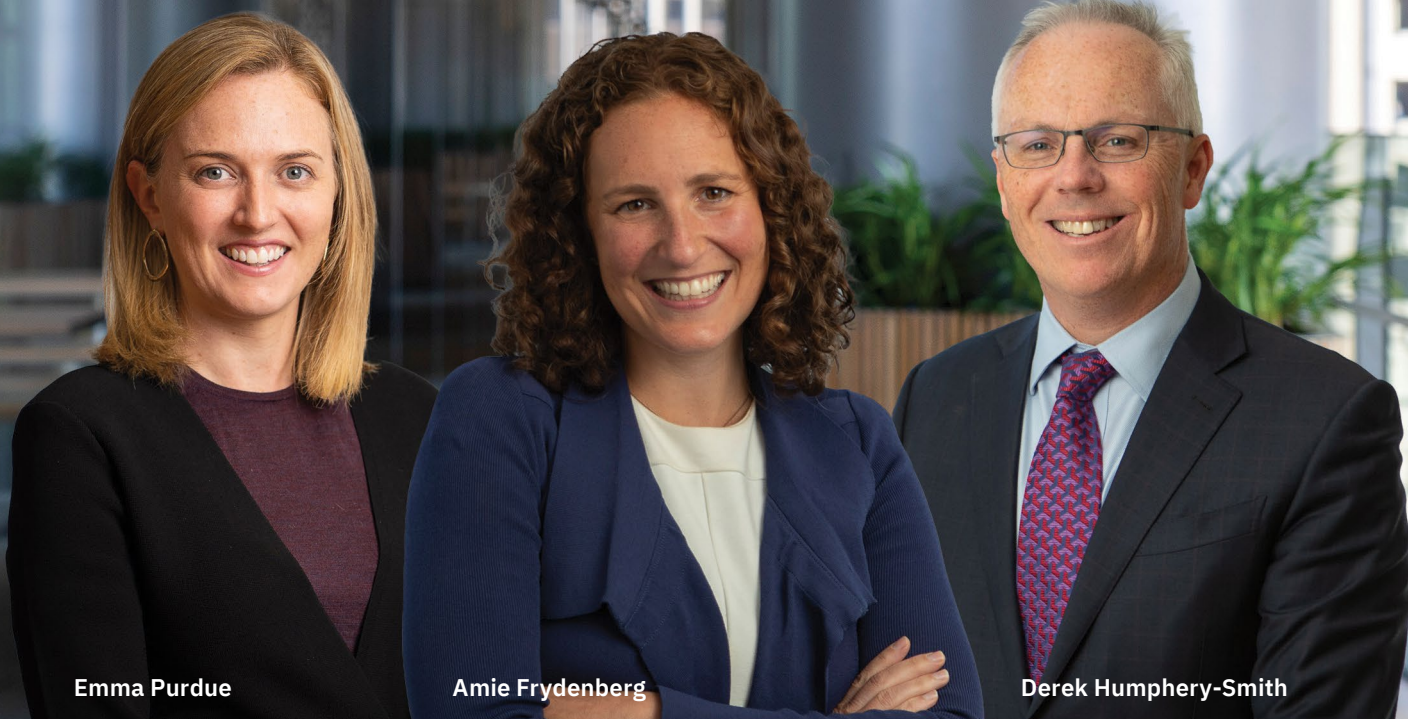We thank Dr Adrian Lim for supplying the patient photos and assistance with the manuscript.

## References

1. Sadick NS, Cardona A. Laser treatment for facial acne scars: a review. *J Cosmet Laser Ther*. 2018;20(7-8):424-35.
2. Goodman GJ, Baron JA. Postacne scarring: a qualitative global scarring grading system. *Dermatol Surg*. 2006;32(12):1458-66.
3. Nangole FW, Agak GW. Keloid pathophysiology: fibroblast or inflammatory disorders? *J Plast Reconstr Aesthet Surg Open*. 2019;22:44-54.
4. Lee Y-J, Lee C-Y, Shin MK. A neglected acne scar type: papular acne scars and their correlations with keloid scars. *Dermatol Surg*. 2021;47(10):1347-51.
5. Patra S, Kaur M, Gupta S. Reduction of Papular Acne Scars With Needle-Guided Radiofrequency Ablation. *Dermatol Surg*. 2021;47(8):1162-3.
6. Mustoe TA, Cooter RD, Gold MH, Hobbs F, Ramelet A-A, Shakespeare PG, et al. International clinical recommendations on scar management. *Plast Reconstr Surg*. 2002;110(2):560-71.
7. Ekstein SF, Wyles SP, Moran SL, Meves A. Keloids: a review of therapeutic management. *Int J Dermatol*. 2021;60(6):661-71.
8. Wolfram D, Tzankov A, Püzl P, Piza-Katzer H. Hypertrophic scars and keloids—a review of their pathophysiology, risk factors, and therapeutic management. *Dermatol Surg*. 2009;35(2):171-81.
9. McGoldrick RB, Theodorakopoulou E, Azzopardi EA, Murison M. Lasers and ancillary treatments for scar management Part 2: Keloid, hypertrophic, pigmented and acne scars. *Scars Burns Heal*. 2017;3:1-16.
10. Goodman GJ. Treatment of acne scarring. *Int J Dermatol*. 2011;50(10):1179-94.
11. Manuskiatti W, Fitzpatrick RE. Treatment response of keloidal and hypertrophic sternotomy scars: comparison among intralesional corticosteroid, 5-fluorouracil, and 585-nm flashlamp-pumped pulsed-dye laser treatments. *Arch Dermatol*. 2002;138(9):1149-55.
12. Jiang Z-Y, Liao X-C, Liu M-Z, Fu Z-H, Min D-H, Yu X-T, et al. Efficacy and safety of intralesional triamcinolone versus combination of triamcinolone with 5-fluorouracil in the treatment of keloids and hypertrophic scars: a systematic review and meta-analysis. *Aesthetic Plast Surg*. 2020;44(5):1859-68.
13. Zaleski-Larsen LA, Fabi SG, McGraw T, Taylor M. Acne scar treatment: a multimodality approach tailored to scar type. *Dermatol Surg*. 2016;42:S139-S49.
14. Aggarwal H, Saxena A, Lubana PS, Mathur R, Jain D. Treatment of keloids and hypertrophic scars using bleomycin. *J Cosmet Dermatol*. 2008;7(1):43-9.
15. España A, Solano T, Quintanilla E. Bleomycin in the treatment of keloids and hypertrophic scars by multiple needle punctures. *Dermatol Surg*. 2001;27(1):23-7.
16. Shaarawy E, Hegazy RA, Abdel Hay RM. Intralesional botulinum toxin type A equally effective and better tolerated than intralesional steroid in the treatment of keloids: a randomized controlled trial. *J Cosmet Dermatol*. 2015;14(2):161-6.
17. Sohrabi C, Goutos I. The use of botulinum toxin in keloid scar management: a literature review. *Scars Burns Heal*. 2020;6:1-13.
18. Zhibo X, Miaobo Z. Intralesional botulinum toxin type A injection as a new treatment measure for keloids. *Plast Reconstr Surg*. 2009;124(5):275e-7e.
19. Lee YI, Kim J, Yang CE, Hong JW, Lee WJ, Lee JH. Combined therapeutic strategies for keloid treatment. *Dermatol Surg*. 2019;45(6):802-10.

20. Patra S, Kaur M, Gupta S. Intralesional radiofrequency with a thin hypodermic needle in the management of papular acne scars. *J Am Acad Dermatol*. 2021;84(6):e259–e60.
21. Wijaya M, Bonilla GM. Facial surgery: scar minimisation and management *Opin Prog Cosmet Dermatol*. 2022;2(1):38–44.
22. Khatri KA, Mahoney DL, McCartney MJ. Laser scar revision: A review. *J Cosmet Laser Ther*. 2011;13(2):54–62.
23. Koike S, Akaishi S, Nagashima Y, Dohi T, Hyakusoku H, Ogawa R. Nd: YAG laser treatment for keloids and hypertrophic scars: an analysis of 102 cases. *Plast Reconstr Surg Glob Open*. 2014;2(12):1–9.
24. Oosterhoff TC, Beekman VK, van der List JP, Niessen FB. Laser treatment of specific scar characteristics in hypertrophic scars and keloid: A systematic review. *J Plast Reconstr Aesthet Surg*. 2021;74(1):48–64.
25. Sklar LR, Burnett CT, Waibel JS, Moy RL, Ozog DM. Laser assisted drug delivery: a review of an evolving technology. *Lasers Surg Med*. 2014;46(4):249–62.
26. Waibel JS, Wulkan AJ, Shumaker PR. Treatment of hypertrophic scars using laser and laser assisted corticosteroid delivery. *Lasers Surg Med*. 2013;45(3):135–40.
27. Abd El-Dayem DH, Nada HA, Hanafy NS, Elsaie ML. Laser-assisted topical steroid application versus steroid injection for treating keloids: A split side study. *J Cosmet Dermatol*. 2021;20(1):138–42.
28. Tawfik AA, Fathy M, Badawi A, Abdallah N, Shokeir H. Topical 5 fluorouracil cream vs combined 5 fluorouracil and fractional erbium YAG laser for treatment of severe hypertrophic scars. *Clin Cosmet Investig Dermatol*. 2019;12:173–80.
29. Sabry HH, Ibrahim EA, Hamed AM. Assessment of laser-assisted delivery vs intralesional injection of botulinum toxin A in treatment of hypertrophic scars and keloids. *Dermatol Ther*. 2020;33(6):e13980.





Emma Purdue

Amie Frydenberg

Derek Humphery-Smith

# YOUR EMPLOYMENT LAW EXPERTS

*Workplace and employment laws are continuously evolving,  
adding to the complexity of running a business.*

Protect your rights and comply with your employer obligations with advice and insight from Australia's leading employment and workplace lawyers.

Access practical advice across a range of topics including:

- workforce management and disputes
- workplace investigations, mediation and training
- sexual harassment complaint management
- employment contracts and policies
- post-employment restraints
- anti-discrimination and equal opportunity
- unfair dismissal and adverse action claims
- employee incentive plans
- industrial relations and enterprise bargaining agreements
- workplace safety and incidents
- 24/7 incident response service: 0411 111 000

## More than a legal advisor

When you require more than just legal advice, Lander & Rogers seeks to minimise risk and de-escalate matters to create cost-effective and focused solutions that avoid costly litigation.

## Learn more

Visit [landers.com.au/employment-workplace](https://landers.com.au/employment-workplace)

## Contact

### Emma Purdue

[epurdue@landers.com.au](mailto:epurdue@landers.com.au)

### Amie Frydenberg

[afrydenberg@landers.com.au](mailto:afrydenberg@landers.com.au)

### Derek Humphery-Smith

[dhumpherysmith@landers.com.au](mailto:dhumpherysmith@landers.com.au)



**LANDER  
& ROGERS**

[landers.com.au](https://landers.com.au)

Brisbane\_Melbourne\_Sydney


# Tips and tricks for revising acne scars – what I have learned over 15 years

Davin Lim<sup>1</sup>

1. Cutis Clinic, Indooroopilly, Queensland, Australia

Correspondence: Davin Lim [info@drdavinlim.com](mailto:info@drdavinlim.com)

Disclosures: *none*



CLICK IMAGE TO LINK TO VIDEO

DURATION\_12:34

**OUTLINE:** Acne scar revision has a diverse algorithm. Whilst studies on various treatment modalities are important to further improve our understanding of skin scars, these tips may add value to the art and science of acne scar revision. Here are my 11 tips.

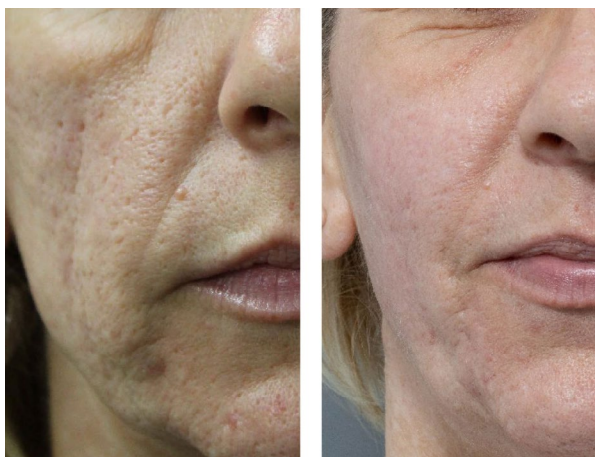**KEYWORDS:** acne scars

Lim D. Tips and tricks for revising acne scars - what I have learned over 15 years. *Opin Prog Cosmet Dermatol* 2022;2(3):83-86.

## 1. Treat age related atrophy

This supports the dermis and redrapes the skin.

Age associated with atrophy and volume loss compounds the atrophic nature of scars. For mature patients with scarring, soft tissue fillers support the dermis and provide volumetric traction to reduce the appearance of scars.



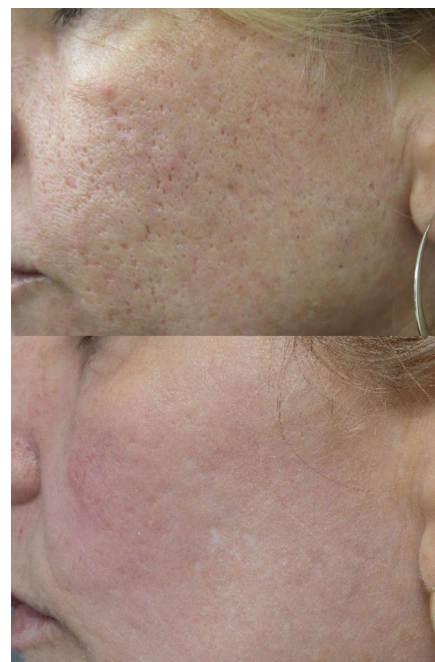**Treat age related atrophy**

TCA – phenol paint by Alison Webb RN  
Dermal filler: Katie Matthew RN

## 2. Don't forget the epidermis

Improve skin quality and luminosity.

Consider skin care, chemical peeling and lasers to improve skin quality, elasticity and hydration. This improves luminosity and the light reflex. Reflectance of light can improve the perception of dermal scarring.

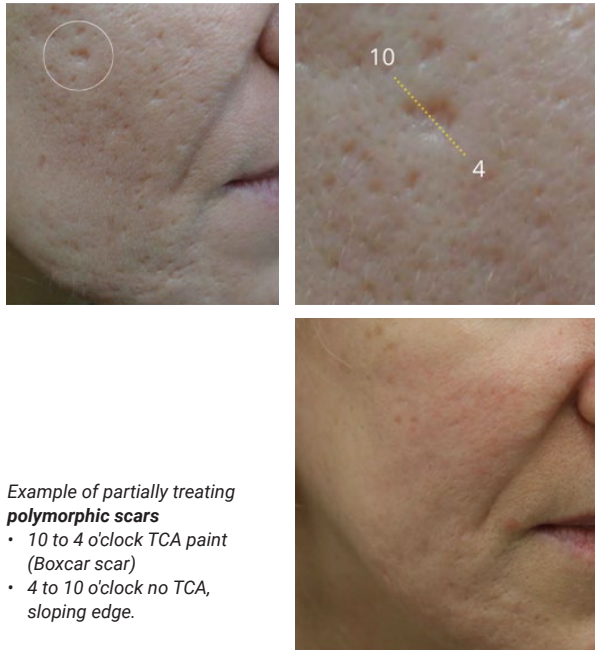

Improvements in skin quality aids in **reflecting** light.  
This yields an overall improvement in the perception of acne scars.



### 3. You don't need to treat the entire scar

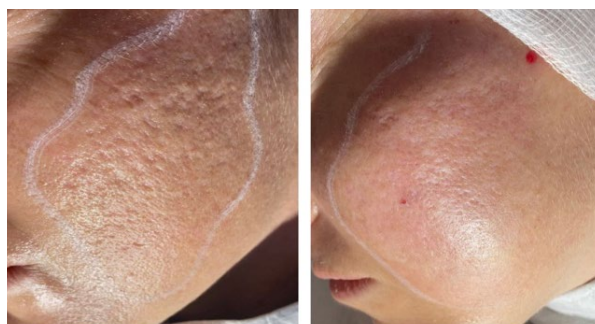Polymorphic undifferentiated acne scars (those that don't fit the Jacob classification) are commonly encountered. Treating the portion of the scar with a suitable modality can result in correction of the treated part. Subsequent modalities including energy devices can treat and improve the remaining areas of the scar.



### 4. Advantages of tumescence

Tumescent analgesia has many advantages, namely:

- Aids in hydro dissection.
- Provides better pain relief.
- Reduces haematomas following subcision.
- Reduces damage to neurovascular bundles.

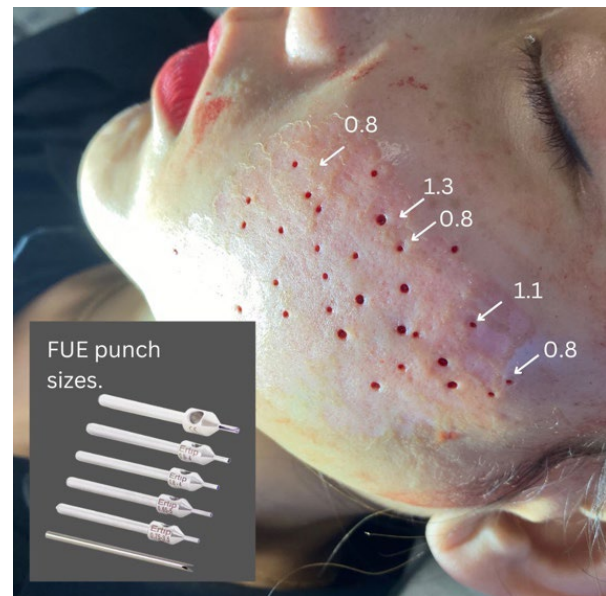


Treatment field prior to tumescent analgesia.

Treatment field after sharp cannula dissection with tumescent analgesia.

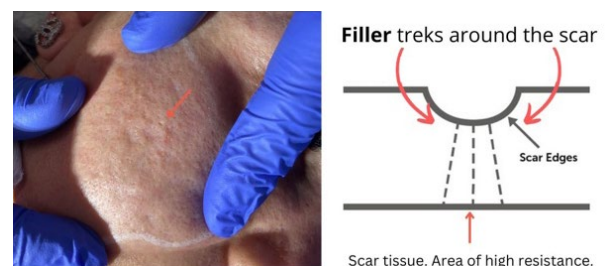
### 5. Repurpose FUE punches to excise scars of various diameters

Follicular unit extraction (FUE) punches come in various sizes ranging from 0.6 mm to 1.5 mm. They are useful for excising ice-pick scars. Compared to biopsy punches, FUE punches remain sharp for well over 100 excisions. Finding the minimum diameter required to excise ice-pick scars will reduce the incidence of spread scars.



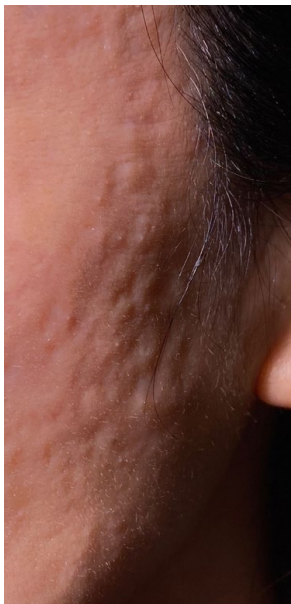### 6. You can't cheat fluid dynamics, the path of least resistance

Subcise either before or at the same time as injecting dermal filler. In areas of fibrosis, soft tissue fillers will follow the law of fluid dynamics and extend around the scar. This results in donutting, or over correction.



**Scar release** should be performed prior to dermal fillers. Biostimulatory HA injectables with a high tan delta are more forgiving as tissue integration is better.





Placement of HA fillers into scar field without prior subcision resulted in over-correction.

For correction of significantly tethered areas of scarring, fillers should ideally be performed after release of scar tissue.

## 7. Don't use dye-dipped paint brushes for TCA or phenol paint

Brushes are useful instruments to apply deep focal peels such as trichloroacetic acid (TCA) or phenol. Always use undyed natural bristle or blended (natural and synthetic) brushes as this prevents pigment tattooing.



Dye free paint brushes



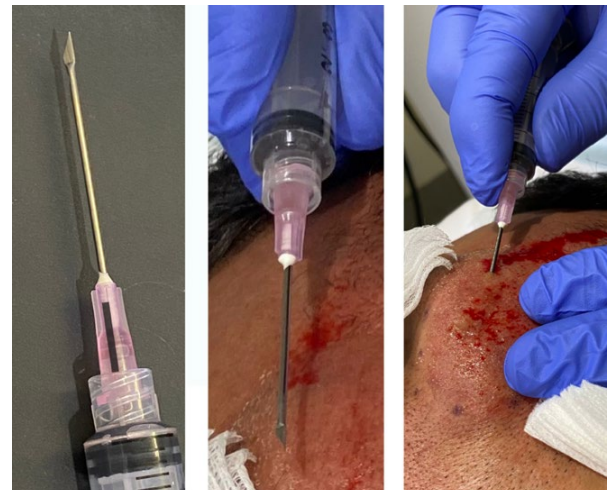Dye heavy paint brushes

The use of dye free paint brushes for TCA – phenol paint will reduce dye tattooing.


## 8. Orientation of subcision cutting instruments

Orientation of cutting blades optimises efficiency and results, and reduces trauma to underlying neurovascular structures. I orientate the unidirectional cutting plane with pre-determined markings on a locking syringe and secure this with a finger on the hub of the Nokor. Other techniques include:

- Marking the hub of the needle.
- Needle holders attached to Nokor needles.
- Most cutting cannulas have hub markings for cutting edge orientation.
- Some blunt blade instruments have pre-cuts on the handle for orientation.

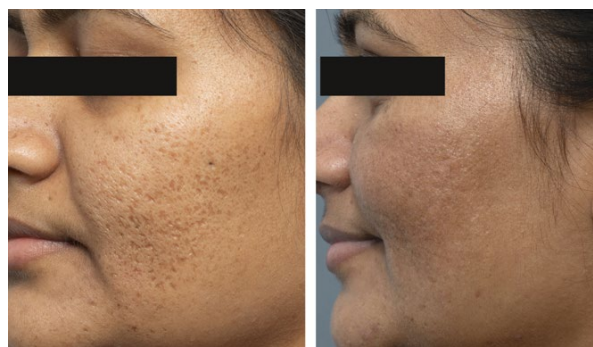
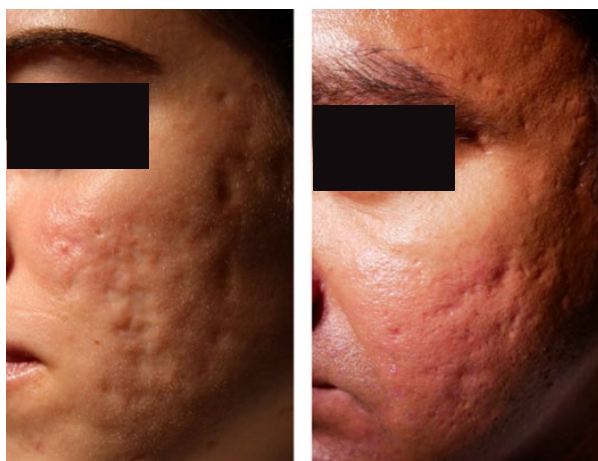
Orientation optimises efficiency and reduces side effects. I use Luer lock syringes to prevent rotation of the cutting needles. Finger tip orientated to the cutting side.



## 9. Tangential lighting reveals all

Angled or tangential lighting is useful for identifying contour changes due to scarring. Tangential light is important if soft tissue fillers are employed as it reduces the chances of overcorrection.



For skin types 4 and above, forewarn patients that post inflammatory pigmentation is expected after treatment with energy devices or focal deep peeling.

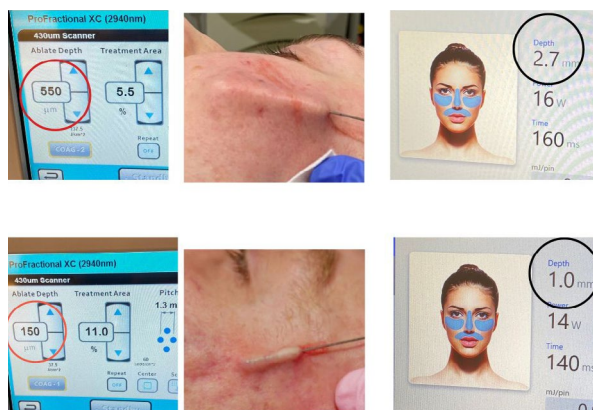
## 11. How to find the optimal depth for energy devices

Use a cannula to dial in the depth of energy devices. Understanding the level of pathology can optimise energy delivery from lasers and energy devices, resulting in better outcomes and reduced adverse events.

## 10. Lasers in darker skin types

Fractional lasers have a lower side effect profile than fully ablative lasers, especially when applied to ethnic skin, however in skin types 4 and above, some degree of post inflammatory hyperpigmentation (PIH) is expected. Modification of lasing techniques can shorten the duration of PIH. This is how I do it:

- Choose a short pulse duration fractional laser, which applies to both ablative and non-ablative lasers.
- Reduce fractional density; typically, 7-25% total coverage.
- Spit the delivery of total density into 2-4 passes, as this reduces bulk heating.
- Apply corticosteroid topically post treatment, continue for 48 hours.
- Increase the treatment interval between treatments to account for PIH.
- Treat PIH early with picosecond lasers.
- Start tyrosinase inhibitors prior to procedures and recommence as soon as re-epithelisation occurs.
- Use the phrase 'this is how darker skin heals' to forewarn PIH changes.



Trust your cannula to assist in dialing in device depth based upon dermal thickness.

# Videos — How I do it

CLICK ICON TO PLAY



PRESENTED BY

**Prof Greg Goodman**

Dermatologist



**Classification and management of less severe surface predominant post acne scarring**



**Classification and management of severe atrophic post acne scarring**



PRESENTED BY

**Dr Davin Lim**

Dermatologist



**Tips and tricks for revising acne scars – what I have learned over 15 years**



**TCA Paint Evolution of TCA CROSS**



**Subcison – how I do it**



**Biostim – how I do it**





Australasian  
Society of  
Cosmetic  
Dermatologists

[www.ascd.org.au/  
medical\\_journal](http://www.ascd.org.au/medical_journal)

## Thank you to the ASCD Industry Partners



Allergan Aesthetics  
an AbbVie company



CYNOSURE® BEAUTIFUL  
ENERGY



LANDER  
& ROGERS

